

# **Refining surgical techniques to optimise middle ear surgery outcomes**

**PhD thesis**

**Székely László Attila MD**

Doctoral School

Semmelweis University



Supervisor: Gábor Polony, MD, Ph.D

Official reviewers: Bakó Péter MD, Ph.D

Kató Erzsébet, MD, Ph.D

Head of the Complex Examination Committee: Farkas Henriette, MD, D.Sc

Members of the Complex Examination Committee: Borkó Rezső, MD, Ph.D

Szirmai Ágnes, MD, Ph.D

Budapest  
2022

## Table of contents

|       |  |    |
|-------|--|----|
| 1     | Introduction   | 4  |
| 1.1   | Development of middle ear surgery                              | 4  |
| 1.2   | Development of stapes surgery                                  | 6  |
| 1.3   | Fundamentals of Otosclerosis and stapes surgery                | 8  |
| 1.3.1 | Anatomy  | 8  |
| 1.3.2 | Definition of Otosclerosis                                     | 9  |
| 1.3.3 | Epidemiology of Otosclerosis                                   | 11 |
| 1.4   | The present and the future of stapes surgery                   | 12 |
| 1.4.1 | Expectations in stapes surgery                                 | 12 |
| 1.4.2 | Laser stapedotomy  | 12 |
| 1.4.3 | Stapes prosthetics   | 13 |
| 1.4.4 | Endoscopic stapes surgery                                      | 14 |
| 1.4.5 | Pharmaceutical adjuvant therapies in stapes surgery            | 15 |
| 1.5   | Summary  | 16 |
| 2     | Objectives   | 17 |
| 2.1   | Rationale  | 17 |
| 2.1.1 | Perioperative IV corticosteroid treatment                      | 17 |
| 2.1.2 | Causes behind unsatisfactory hearing results after stapedotomy | 18 |
| 2.1.3 | Early postoperative taste disturbance after middle ear surgery | 18 |
| 2.2   | Hypotheses   | 19 |
| 2.2.1 | Hypothesis 1   | 19 |
| 2.2.2 | Hypothesis 2   | 19 |
| 2.2.3 | Hypothesis 3   | 19 |
| 2.2.4 | Hypothesis 4   | 20 |
| 2.2.5 | Hypothesis 5   | 20 |
| 2.3   | Patients and methods   | 21 |
| 2.3.1 | Evaluation of perioperativ IV corticosteroid treatment         | 21 |
| 2.3.2 | Evaluation of revision stapedotomies                           | 23 |
| 2.3.3 | Early postoperative taste disturbance after middle ear surgery | 24 |

|     |   |           |
|-----|---|-----------|
| 3   | Results   | <b>26</b> |
| 3.1 | Mid-term evaluation of perioperative IV corticosteroid treatment efficacy on audiological outcome following CO <sub>2</sub> laser stapedotomy | 26        |
| 3.2 | The role of periprosthetic scar tissue formation in the development of unsatisfactory hearing results after stapedotomy                       | 30        |
| 3.3 | Early postoperative taste disturbance after middle ear surgery  | 33        |
| 4   | Discussion  | <b>36</b> |
| 5   | Conclusions   | <b>42</b> |
| 6   | Summary   | <b>44</b> |
| 7   | References  | <b>46</b> |
| 8   | Bibliography of the candidate's publications  | <b>57</b> |
| 9   | Acknowledgements.   | <b>58</b> |

## **List of Abbreviations**

TM- tympanomeatal

ISJ-incudostapedial joint

AC-air conduction

BC-bone conduction

ABG-air-bone gap

PTA- pure tone average

LPI-long process of incus

TOST- two one-sided t-tests

S First group: patients received corticosteroid perioperatively

nS Second group: patients did not receive any corticosteroid perioperatively

ASNHL – acute sensorineural hearing loss

VAS- Visual analogue scale

LSCC- Lateral semicircular canal

# 1 Introduction

## 1.1 Development of middle ear surgery

The first surgical interventions in the region of the temporal bone could be credited to Hippocrates (c. 460 – c. 370 BC) [2] and Galen (c.130 - c.210 AD) [3] who wrote about the necessity of draining an infected ear. In the beginning of middle ear surgery, the only goal was to cure the infection and save the patient's life. Before the era of antibiotics, that goal remained the main motivation behind the development of otologic surgery.

The first documented mastoidectomy was reported by Johannes Riolanus the Younger in 1671 [4], however he still only discussed the removal of pus and infected tissues. The first surgeon who deliberately started to remove the mastoid bone to obtain access for drainage to middle ear infection was Jean-Louis Petit (1674 – 1750) [5]. He began using a hammer, chisel, and drills during mastoid surgery. Despite this treatment method not being accepted by his colleagues, he reported fairly good results and became an unequalled expert in mastoid surgery in his time.

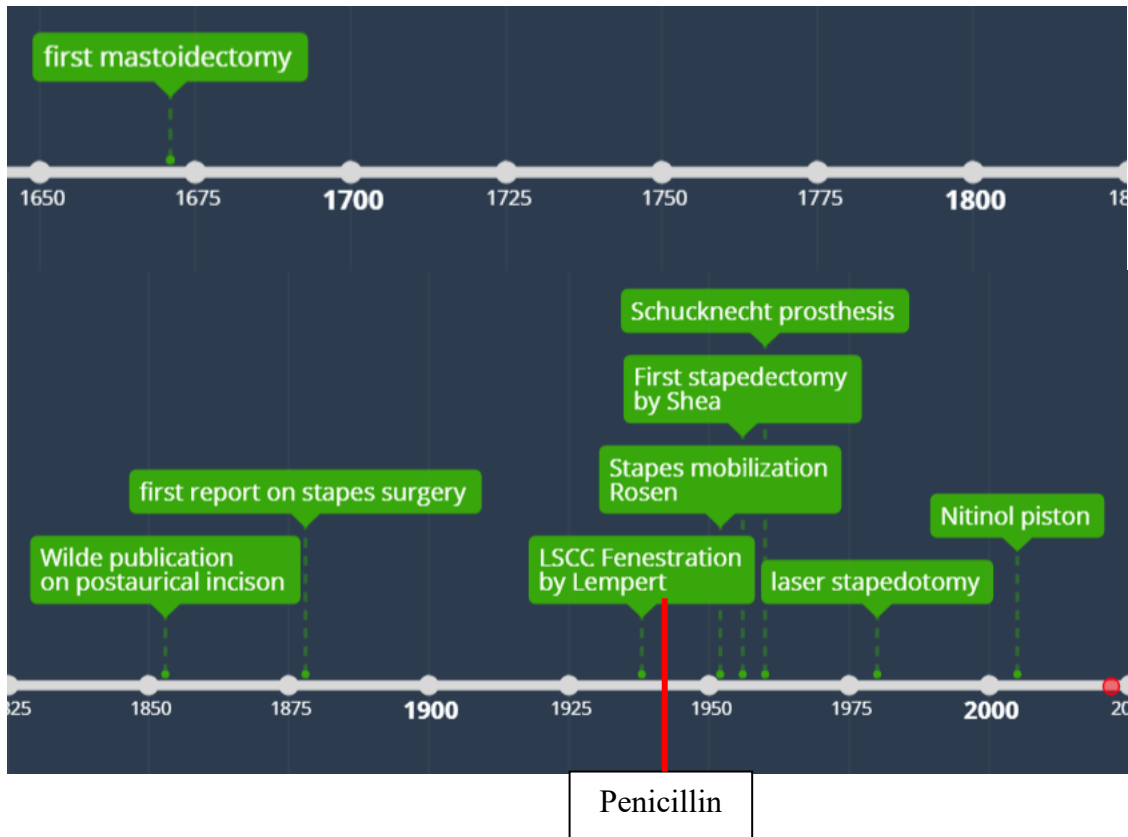
Beginning in the 18<sup>th</sup> century some attempts began to emerge not only to cure life-threatening infections, but also to cure deafness. J.L. Lasser was the first person who reported the connections of the mastoid [6]. During the drainage of a retroauricular abscess, he irrigated the cavity and noticed discharge from the ear canal and from the nose. Three weeks later the patient presented with improved hearing.

The beginning of the modern era of otologic surgery could be dated to 1853, the year Joseph Toynbee placed a rubber disc on a perforated tympanic membrane, resulting in hearing improvement [7], while in the same year Sir William Wilde published his work describing postauricular incision and the removal of the cortical bone of the mastoid [8]. The next 80 years of otology were still mainly focused on the treatment of infective diseases and the development of mastoid surgery, with Swartz, Von Troltschin, and Von Bergmenn describing more efficient and sophisticated methods of mastoidectomy.

At the same time, the aim of otology began to shift towards functional results. In 1876, Kessel reported on his experience with stapes surgery [9]. His method was a transmembrane stapes mobilization or stapedectomy to cure hearing loss caused by stapes

ankylosis. The intervention was performed without proper illumination or magnification and without sealing the oval window. Following in Kessel's footsteps, similar surgeries were performed in Europe and in the U.S. Frederick L. Jack was one of the otologists in the U.S. who performed stapes surgery at that time [10]. He reported a case where the tympanic membrane retracted and healed over the oval window, leading to a mobile membrane and a stable hearing result for at least 10 years. His finding was rediscovered some decades later and was the foundation of modern stapes surgery. Despite some promising hearing results, the number of detrimental complications like meningitis and labyrinthitis led to an end of stapes surgery at the 6th International Otology Congress in London, claiming that stapes surgery was "useless, often mutilating, and dangerous." [11]

The first true tympanoplasty was performed in 1878 by Berthold who desepithelialized the membrane remnant by applying plaster and reconstructing it by overlaying a skin graft [12]. But the revolution in middle ear surgery came only in the 1950s thanks to the wide accessibility of antibiotics and later the introduction of operating microscopes and microsurgical instruments by Wullstein. By this time, the main goal of these surgeries was to improve hearing and to protect the middle ear from possible future infections [13].



**Fig. 1.** The timeline of stapes surgery evolution Own. figure.

## 1.2 Development of stapes surgery

The phenomenon of stapes footplate fixation was originally described by Antonio Maria Valsalva in 1704 [14] during cadaver dissections. In 1841, Toynbee established the connection between stapes fixation and deafness. In his words, “osseous ankylosis of the stapes to the fenestra ovalis was one of the common causes of deafness”. The first in-depth histologic report on this topic was by Adam Politzer, who in 1893 described stapes fixation as a pathology of the labyrinthine capsule and referred to this pathology as otosclerosis [15]. In stapes surgery, the only goal is to achieve hearing gain in an otherwise healthy ear without further complications. Due to the nature of this high-risk delicate surgery, it remained forbidden for a long time. Bypassing the risk of stapes mobilization, Maurice Sourdille developed a three-stage retroauricular fenestration technique to open a window on the lateral semicircular canal [16], a technique which was later refined by Julius Lampert in 1938 to a one-stage endaural procedure[17]. It was in 1952 when Samuel

Rosen returned to stapes mobilization. He originally performed the fenestration technique of Lempert but with a mobility check of the stapes superstructure. Eventually he mobilized the stapes footplate which was noticed by a patient who was being operated on under local anaesthesia [18]. Following this case, he developed a transcanal standard mobilization procedure – a relatively safe and less invasive method, but the recurrence rate remained very high. This development was a decisive step towards modern otosclerosis surgery with a renewed possibility to manipulate the stapes. However, the real breakthrough and the beginning of the current era has to be credited to John Shea who introduced the stapedectomy method in 1956 [19]. He was a clinical fellow at the University of Vienna when he encountered the report of Frederick L. Jack about the patient who had the tympanic membrane healed over the oval window, resulting in stable hearing improvement. Understanding the significance of this case, he developed a teflon stapes prosthesis and inserted it over a connective tissue coverage of the oval window, thereby reconstructing the ossicular chain in the middle ear. While at this time Shea was widely criticized due to the dangers of removing the stapes footplate, this procedure still serves as the principle of stapes surgery.

Since the original description of stapedectomy, numerous adjustments have been made to optimise the results. Thanks to this continuous progression, stapes surgery is now an essential, safe, and efficient otologic procedure. One of the main improvements in the modern era was the introduction of stapedotomy versus complete footplate removal, which has led to significantly better hearing results and to less postoperative morbidity [20]. Further improvements could be seen concerning the introduction of laser-stapedotomy in 1980 by Perkins [21]. During the last four decades, various laser techniques have been utilized in otologic surgery with clear advantages over conventional techniques [22]. However, no clear conclusion could be drawn regarding the comparative efficacy of different laser types. According to available data, CO<sub>2</sub> and KTP seem to be superior compared to other solutions [23]. At the same time, the development of stapes prostheses was also remarkable. The basic requirements of a prosthesis are a secure connection to the ossicular chain and proper sealing of the opening towards the inner ear. It was Schuknecht in 1960 who initiated the use of the widespread steel wire-adipose tissue prosthesis [24]. Compared to Shea's original prosthesis which worked basically as a strut between the oval window and the incus, the steel wire could be crimped onto the long process of the incus. In this way a more secure connection could be obtained, while the connective tissue



plugged the stapedectomy hole. The availability of more precise fenestration techniques like the microdrill and the laser facilitated the introduction of piston-shaped prostheses. Thanks to these delicate methods, the piston matches the oval window perforation precisely enough to obtain a perfect seal and to leave the connective tissue plugging. The most recent prosthetics innovations are the soft clip and thermal crimping solutions. Soft clip crimping was introduced by Wengen [25] at the beginning of 21<sup>st</sup> century; it is basically a self-crimping attachment to the incus, based on a spring-like mechanism. The application of a shape-memory Nitinol prosthesis was first reported in 2005 [26]; in this case the crimping is done via thermal activation ideally without any mechanical manipulation. The aim of both these later modifications is to obtain a secure and long-lasting acoustic coupling at the incus and therefore to mitigate the risk of postoperative LPI (long process of incus) necrosis via more precise and less traumatic crimping.

### 1.3 Fundamentals of Otosclerosis and stapes surgery

#### 1.3.1 Anatomy

The human ear consists of three major parts: the outer, middle, and inner ear. The pinna and ear canal belong to the outer ear. The pinna and the lateral part of the canal are formed by cartilage covered with skin, while the medial part of the canal is formed by the os tympanicum – part of the temporal bone – which is covered with skin as well. The functions of this region are protection and sound transduction to the middle ear. The medial border of the outer ear is the tympanic membrane, a three-layer membrane belonging to the middle ear. It is the most lateral part of the mechanical sound coupling system which translates airborne acoustic waves into waves travelling in the inner ear liquid (perilymph). Behind the tympanic membrane the tympanic cavity can be found. It is an air-containing chamber insulated with mucosa. It also contains the three hearing ossicles and their suspensory ligaments, which are the main parts of the coupling system. It has several connections to surrounding structures, which are the round and oval window towards the inner ear, the aditus ad antrum towards the mastoid, and the Eustachian tube towards the epipharynx. Nerve structures also can be found in this region, like the chorda tympani, Jacobson nerve, and sympathetic fibres from the carotid chain forming the

tympanic plexus, but the most important is the facial nerve, which runs above the oval window on the medial wall. It is usually enveloped in a bony canal, but it is frequently dehiscent at the tympanic segment. The chorda tympani nerve is a branch of the facial nerve, which runs on the medial side of the tympanic membrane, crossing the middle ear between the handle of malleus and the incus. It arises from the main branch of the facial nerve near the stylomastoid foramen and travels in a bony canal until reaching the middle ear. On the anterior side of the middle ear, it leaves through the petrotympanic fissure to the infratemporal fossa[27]. Chorda tympani is responsible for the taste sensation of the ipsilateral anterior two-thirds of the tongue and for secretomotor innervation of submandibular and sublingual glands. The three hearing bones are the malleus, which is the most lateral and is anchored to the eardrum; the incus which connects the other two and acts as a lever; and the stapes which is the most medial one – and the smallest bone of the human body – connecting the ossicular chain to the inner ear fluid. The stapes works as a vibrating piston during sound transmission. It has a head, neck, two crurae, and a footplate which forms the border with the inner ear. This footplate sits in the oval window. On the medial side of the stapes footplate is the start of the scala vestibuli – one of the three fluid containing cavities of the cochlea. These three parts are the scala vestibuli and the scala tympani, which are continuous at the apex of the cochlea (i.e., the helicotrema), and the scala media, or cochlear duct. The scala tympani ends at the round window with a membrane. The travelling wave of the cochlea forms in the perilymph of the scala vestibuli and scala tympani, between the oval and round window, induced by stapes footplate vibration. This phenomenon is the first part of the electromechanical coupling of sound in the inner ear.

### 1.3.2 Definition of Otosclerosis

It was Valsalva who discovered stapes fixation as a pathology, but the original description of otosclerosis based on histopathological definition was published by Adam Politzer in 1893 [15]. According to current knowledge, otosclerosis is a multifactorial bone disease of the inner ear capsule, with genetic and environmental causes [28]. The familiar clustering of the disease is a well known phenomenon. Most data in this topic suggest a pattern of autosomal-dominant transmission with incomplete penetrance, with multiple genes defects

[29]. In addition to the genetic background, there is a possibility that measles infection also has etiologic role in the development of otosclerosis. Measles RNA has been identified from osteosclerotic lesions, and elevated levels of IgG specific for measles virus antigens has been found in the perilymph [30]. Since otosclerosis is more frequent in women compared to men it was thought that elevated levels of estrogen during pregnancy may facilitate the progression of the disease [31]. There was controversy concerning this topic in the literature from the beginning. According to recent publications, the linkage between pregnancy and progression of otosclerosis is not likely [32, 33].

The main histologic landmark of this disease is abnormal bone remodelling in the temporal bone. This abnormal bone production causes the fixation of the footplate. The most common area involved is the area anterior to the oval window, which is affected in 96% of cases [34]. One belief is that the embryologic remnant called “fissula ante fenestram” could be the focus of origin, however there are cases when the otosclerotic focus is distinct from this area and therefore does not support this idea [35]. In cases of advanced otosclerosis the disease could affect the cochlea as well.

Clinical otosclerosis is when stapes fixation is associated with conductive or mixed hearing loss. Diagnosis of this condition is based on audiologic testing. Imaging studies are not routinely needed for diagnosis, however they can provide useful information in specific cases. Pure tone audiometry is still the gold standard for the description of middle ear performance. In cases of stapes fixation, an ABG (air-bone gap) of at least 10-15 dB is present. Usually the hearing loss is worse in the low frequencies. The BC at the beginning of the otosclerotic process is usually normal, but a decrease at 2000Hz can often be seen. This notch-like BC decrease is called the Carhart notch. This is a frequent sign of otosclerosis, however it is not specific to the site of ossicular chain fixation, and is not always found in otosclerosis cases [36]. The reason behind this phenomenon is still not completely understood.

About 30% of otosclerosis patients develops clinically significant (>10dB) sensorineural hearing loss [37]. In advanced stages mixed hearing loss is predominant, most likely due to cochlear involvement which causes hyalinization in the cochlea [38]. The otosclerotic involvement of cochlear endosteum causes stria vascularis atrophy via hyalinization of the spiral ligament. This leads to disruption of the potassium recycling mechanism thus the endocochlear potential and inner ear function will be damaged [39]. Outer hair cell loss is

also have been found, but most likely it is not a major cause behind sensorineural hearing loss [40].

Other audiological tests are also in use in the workup. Tuning fork tests are helpful in the diagnosis, with Weber and Rinne giving information about the type of hearing loss, while the Gellé test is specific to ossicular chain fixation. The 512 Hz Rinne test negativity means a minimum of 25 dB ABG while the test with 1024Hz tuning fork will be negative from 30dB. Tympanometry usually shows decreased middle ear compliance referred as an “As” tympanogram. In case of stapes fixation, the resonance frequency increases. Multifrequency tympanometry is a helpful tool for detecting middle ear resonant frequency. The diagnostic accuracy of multifrequency tympanometry outperforms standard low frequency tympanometry in case of ossicular chain fixation [41], thus if available it should be used for stapes fixation diagnosis. The absence of stapedial acoustic reflex in the case of small ABG is also a useful sign that could help to differentiate between ossicular chain fixation and third window syndromes.

### 1.3.3 Epidemiology of Otosclerosis

The prevalence of clinical otosclerosis ranges between 0.1% and 0.4 % [42-44]. The involvement is usually bilateral but asymmetrical [45]. It is more common in female patients; about 65% of clinical cases are female [46]. The onset of the disease is usually in the third and fourth decades [46].

Exact demographic data are not available about the Hungarian otosclerosis population, but the data of the Swedish Quality register for otosclerosis were published [44] in 2017. Because of the population similarity between Sweden and Hungary (10.35 vs. 9.75 million), the former can serve as an estimation for Hungarian numbers. According to these data, 2,493 stapes surgeries were performed in six years, equating to about 415 surgeries performed annually. Over the last ten years this number ranged between 380 and 580 surgeries. The surgeries were performed at 26 clinics by approximately 50 surgeons. The number of procedures at single institutions was between 8 and 402 cases over six years, translating to 1 to 67 cases per year. In Hungary fewer institutes and fewer surgeons perform this kind of surgery, while the case-per-institute numbers are similar. Applying our experience to the above data, our assumption is that Hungary has about half the

number of clinics and surgeons involved in stapes surgery compared to Sweden. Following this logic, the number of stapes surgeries in Hungary could be around 200 per year.

#### 1.4 The present and the future of stapes surgery

##### 1.4.1 Expectations in stapes surgery

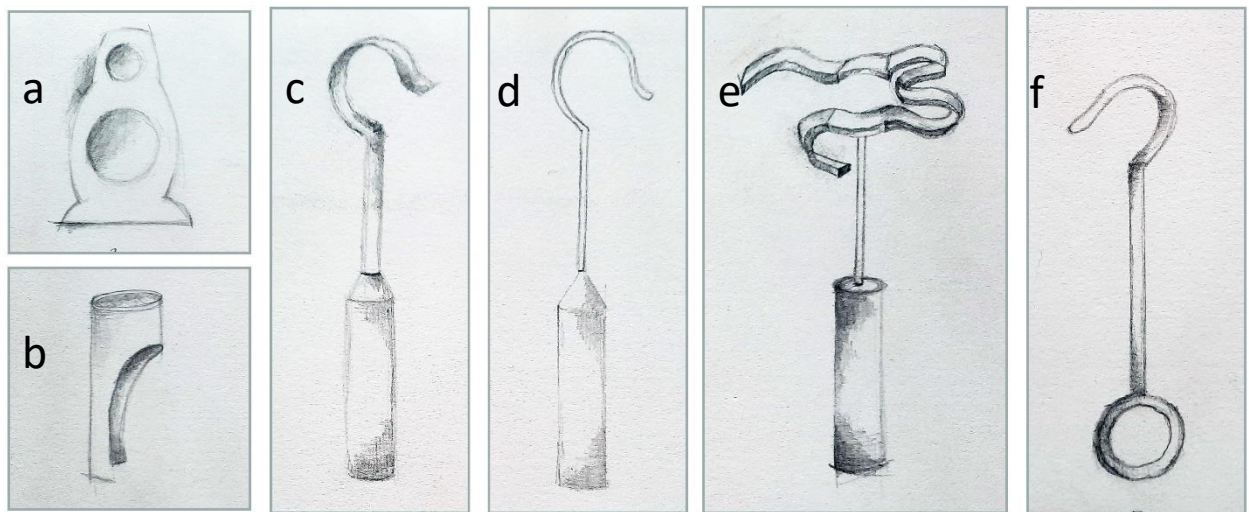
Stapes surgery is an essential procedure in modern otology with very high success rates and with low postoperative morbidity. However, due to the high expectations of this intervention, the room for error is very narrow, while there are plenty of areas for further improvements. If we consider the average hearing gain of about 20dB after surgery [47], then a 2dB difference in our results means a 10% improvement. From another point of view, surgical success (which means closing ABG below 10 dB [48]) is achieved in about 90% of cases [47]. Although this is a high number, it means that even in otologic centres one in ten patients could be subject to revision surgery. The stability of hearing results could be also an area to improve, as despite the latest techniques the mid- and long-term complications like adhesion formation, incus long crus necrosis, oval window re-obliteration etc. could cause a significant challenge for the surgeon. Most frequent complications include tympanic membrane perforation, chorda tympani injury, vertigo, and minor surgical site infections. While major problems like deafness, facial palsy, labyrinthitis are extremely rare but existent phenomenon[49]. Our goal is to avoid intra- and postoperative complications while optimizing audiological outcomes. In a surgical field with such high expectations, even minor developments could be very important.

##### 1.4.2 Laser stapedotomy

Laser stapedotomy is an increasingly widespread method, with the CO<sub>2</sub> and KTP lasers as leading devices. However, emerging solutions like the Diode laser also show promising results [50]. In our department the CO<sub>2</sub> laser is preferred due to its powerful, yet very precise and atraumatic properties. One of the advantages of the CO<sub>2</sub> laser is its low

penetration depth into liquids, which means 0.01mm in the perilymph. At the same time it is capable of “single shot” fenestration of the footplate with a pre-set diameter. This method essentially guarantees a precise piston fit into the stapedotomy hole. In our opinion this could be the main advantage over other techniques when the stapedotomy is performed by manipulating with a handpiece (skeeter or KTP for example). The application of a laser has an advantage not only when manipulating the footplate, but also when it is used for stapes superstructure removal or for mobilizing other middle ear ossicles, and for thermal piston crimping as well. All the utilisations mentioned above lead to less mechanical manipulation thus less mucosal trauma and less chance for ossicular chain injury in the tympanic cavity. The proximity of the facial nerve and the stapes footplate must be taken into consideration during any stapedotomy method. In the case of laser stapedotomy, especially if the tympanic segment of the facial canal is dehiscant, further caution is needed to avoid any possible injury. If caudal dehiscence of the canal is present, this area could be vulnerable to a reflected laser beam, whereas injury to this area using straight mechanical instruments is not possible.

#### 1.4.3 Stapes prosthetics



**Fig. 2.** Stapes prosthesis evolution. a, first prosthesis by Shea; b, Shea strut; c, Richards platinum-fluoroplastic; d, Schuknect stainless steel-fluoroplastic; e, Soft-clip; f, House wire loop stainless steel. Own figure.

The combination of a fluoroplastic piston and platinum shaft is currently a popular choice in stapes prosthetics. Fluoroplastic is a light bioinert material with very low friction,

making it ideal for oval window coupling. Other materials like stainless steel and titanium are also in use. The use of stainless steel is in decline. It is MRI safe, but is the only material from the above list which shows movement during MRI scanning, however this movement is subclinical. A special version of titanium is nitinol, a nickel-titanium alloy which returns to its original shape when heated. Nitinol prosthetics are manufactured at the size of the incus long crus, then are stretched to the applicable size. The piston diameter is still a topic of debate. They are manufactured from 0.3 mm to 0.8mm. The most commonly used sizes are 0.4 mm and 0.6 mm. A recent systematic review did not find a significant functional difference between these two sizes [51], however another metanalysis [52] claimed that 0.6 mm has a clear advantage over 0.4 mm, with a 4 dB better ABG result.

Compared to a mobile stapes, a stapes prosthesis causes the same fluid displacement in the inner ear until 700 Hz; above this frequency native stapes outperform any piston [53]. In the 500-4000 Hz area a phase delay could also be observed. These phenomena could be especially problematic when serious sensorineural hearing loss is accompanied preoperatively with ABG. In these cases, powered middle ear implants have been utilized simultaneously with the aim to provide more hearing gain and to optimise the frequency response curve, especially at middle and high frequencies. Promising results have been reported both with Cochlear DACS and MED-EL VSB devices [54, 55]. The VSB floating mass transducer could be implanted in the middle after standard stapedotomy in a one-step procedure, combining the advantages of the two methods. This solution is called ‘power stapes’ which could be applied in cases with severe mixed hearing loss, however routine usage of this method is not widely adopted. Cochlear implantation could also be an option of rehabilitation in very advanced otosclerosis [56].

#### 1.4.4 Endoscopic stapes surgery

The introduction of endoscopes in otologic surgery is a very active topic today. This is another step towards minimal invasive surgery. The main advantage of the endoscopic operation is better visualization due to wider angles of view. By using the endoscopic technique, the endaural incision and lateral atticotomy are unnecessary to obtain an adequate view of the middle ear. On the other hand, one-handed manipulation, especially in the case of bleeding or during the handling of the prosthesis, is challenging. In the hands

of an experienced surgeon endoscopic results could be comparable to microscopic techniques [57].

#### 1.4.5 Pharmaceutical adjuvant therapies in stapes surgery

Sensorineural hearing loss could easily occur during stapes footplate manipulation, which is a detrimental complication. It could result in major hearing loss – fortunately a very rare situation in the modern era – or there could be only a minor loss which still could determine the efficacy of the results. Most of the development in stapes surgery concentrates on minimizing inner ear trauma and maximizing audiological gains. However, even with the most atraumatic technique the chance of minor inner ear damage cannot be excluded. The cochleoprotective effect of corticosteroids has already been shown [58, 59] and is widely utilized in otology practice. The exact pharmaceutical effects of corticosteroids in the inner ear are still not completely understood. The most cited effects are fluid regulation through ion and water homeostasis and inhibition of inflammatory responses. The corticosteroid receptors were found in highest concentration in the spiral lamina, inner and outer hair cells, and in spiral ganglion neurons [60]. Anti-inflammatory effect is the consequence of cytokine synthesis and release inhibition and intracellular cytokine antagonist effect [61]. While NF- $\kappa$ B pathway modulation could play a major role in neuroprotection in the inner ear.[62]. Upregulation of homeostasis genes thus optimising fluid regulation also could be an important factor in their therapeutic effect [63].

In stapes surgery the positive effect of perioperative corticosteroid administration is not clear. Some clinical researchers have found no significant changes in audiological outcomes [64, 65]. However, in other otologic settings like cochlear implantation, a protective inner ear effect by reducing vestibular trauma and electrode impedances has been shown [66]. There are also multiple nonclinical results showing a positive effect in cases of cochlear trauma and otologic procedures [67-69]. This topic needs further investigation in the future. In some cases, the indication of corticosteroid treatment during surgery comes from the anaesthesiology, and it is possible not to take these occasions into consideration when evaluating otologic results, making this topic more unclear.



## 1.5 Summary

During the long history of middle ear surgery, the surgical goals have completely changed. In the beginning the main motivation was to combat life-threatening infective conditions, but we can also observe that the desire to heal deafness was also present from very early. The evolution of antibiotics was a decisive step in the beginning of modern otologic surgery. From the 1950s a new era of microsurgery was born, thanks to technological progress. From this point on, the focus shifted towards functional results. Presently the aim is not only to heal acute infection or to achieve an infection-proof middle ear, but to ensure good hearing and vestibular function. Stapes surgery is a special kind of middle ear surgery where hearing gain is the primary focus. The difficulty of this situation is well known to every otologic surgeon, however according to most of the opinions it is one of most rewarding and enjoyable procedures otology can offer. While modern middle ear surgery is a well-established area with good results and with ample knowledge, the expectations are also very high, and as discussed above there is still room for improvement. Some of the most important objectives for an otologist in the current era is to acquire the abundant knowledge generated over the decades and to refine the utilized techniques to maximize functional outcomes. According to the amount and quality of the pre-existing knowledge, the main areas of progress are currently found in technical advancements: implantable devices, biocompatible materials, 3D modelling and robotic surgery, and pharmaceutical therapies, and this will always remain the foundation of surgery in the meticulous optimisation of surgical methodology.

## 2 Objectives

### 2.1 Rationale

In our department we are running a busy otologic practice, performing significant numbers of middle ear operations. The original aim of our research was the additional refinement of these procedures. The main point of interest was the understanding of chorda tympani related morbidity after middle ear surgeries and the optimisation of audiologic results in cases of stapes surgeries. To achieve the former goals, we wanted to prove the efficacy of CO<sub>2</sub> laser stapedotomy, to understand the reasons behind unsatisfactory hearing results, and to clarify the role of adjuvant pharmaceutical therapy.

#### 2.1.1 Perioperative IV corticosteroid treatment

As was discussed in the previous chapter, the cochleoprotective effect of corticosteroids is a well-known phenomenon. The systemic administration of these drugs in cases of acute inner ear damage like ASNHL (acute sensorineural hearing loss) is part of everyday practice [59]. During stapes surgery it is always crucial to avoid any inner ear damage, but even with the most atraumatic techniques the chance of a minor decrease in cochlear or vestibular function cannot be ruled out. These situations will result in acute vestibular dysfunction or in an unsatisfactory hearing result. Even in cases with acceptable hearing outcomes marginal gains could be significant and beneficial for patients. The reason behind perioperative adjuvant corticosteroid therapy is to achieve a protective effect against any thermal or mechanical damage to the inner ear during surgery. However, considering the possible side effects, the use of these drugs requires evaluation based on solid evidence.

The aim of our research was to investigate the possible positive effects of perioperative systemic methylprednisolone therapy on the outcomes of stapes surgery. Our main interests were the middle term audiological results and early postoperative morbidity.

To minimize the chance of any inner ear dysfunction and to optimise middle ear and piston function, stapedotomies are performed with a CO<sub>2</sub> “single shot” technique. The utilization of this technique is well documented in the literature [23].

### 2.1.2 Causes behind unsatisfactory hearing results after stapedotomy

The second part of our research was aimed at identifying the reasons behind unsatisfactory hearing results, especially in cases where the main cause of failure is inadequate middle ear function. Revision stapes surgery offers an excellent opportunity to examine the middle ear situation and to identify the reasons behind failure. The surgical success of stapedotomy is between 87-97% in the literature [47], which means that 3-13% of patients need at least a second surgery. Generally speaking, revision surgeries are more difficult to perform than primary interventions, and their audiological results are inferior [70]. This observation underlines the importance of the first surgery and the need to understand the nature of failures. According to the literature, adhesion formation in the tympanic cavity is one of the most common findings during revisions [71, 72]. However, the influence of this adhesion formation on audiological outcomes is not clear. Our purpose was to find the most common and most influential postoperative reasons for persistent ABG, and to clarify the relationship between adhesion presence and its impact on hearing. The focus was on intratympanic mechanical dysfunctions, especially on postoperative adhesion formation.

### 2.1.3 Early postoperative taste disturbance after middle ear surgery

In modern middle ear surgery, the lowering of postoperative morbidity is crucial. Taste disturbances after such interventions are one of the most common complications. This is the consequence of chorda tympani injury, which nerve is responsible for the taste sensation of the ipsilateral two-third of the tongue and for the parasympathetic innervation of submandibular and sublingual glands. Due to the localisation of the nerve, it can be affected during various surgeries. The first segment travels in a bony canal which is affected during mastoid surgery, while the second segment travels in a mucosa fold in the middle ear on the medial side of the eardrum[27]. This part of the nerve travels through the

surgical field in all cases when tympanic membrane is elevated (tympanoplasty, stapes surgery etc.). The frequency of taste disturbances after surgery could be around 50%, even if the continuity of the nerve is preserved [73]. Chorda tympani injury could also lead to salivary gland dysfunction [74].

Our goal was to investigate the effect of mechanical manipulation on nerve function, and to see the complication rates in different subtypes of middle ear surgery.

## 2.2 Hypotheses

### 2.2.1 Hypothesis 1

Our hypothesis was that the CO<sub>2</sub> laser is an atraumatic solution for performing stapedotomy, thus adequate ABG and hearing gains can be achieved while causing no decrease in sensorineural hearing function.

### 2.2.2 Hypothesis 2

The hypothesis was that perioperatively administered IV methylprednisolone therapy could have a protective effect against minor intraoperative inner ear damage in cases of CO<sub>2</sub> laser stapedotomies. Therefore, audiological results could be superior to those of the control group.

### 2.2.3 Hypothesis 3

The hypothesis was that inflammation induced by surgery and the consequent scar tissue formation in the tympanic cavity could be the major reasons behind compromised ABG gain.

#### 2.2.4 Hypothesis 4

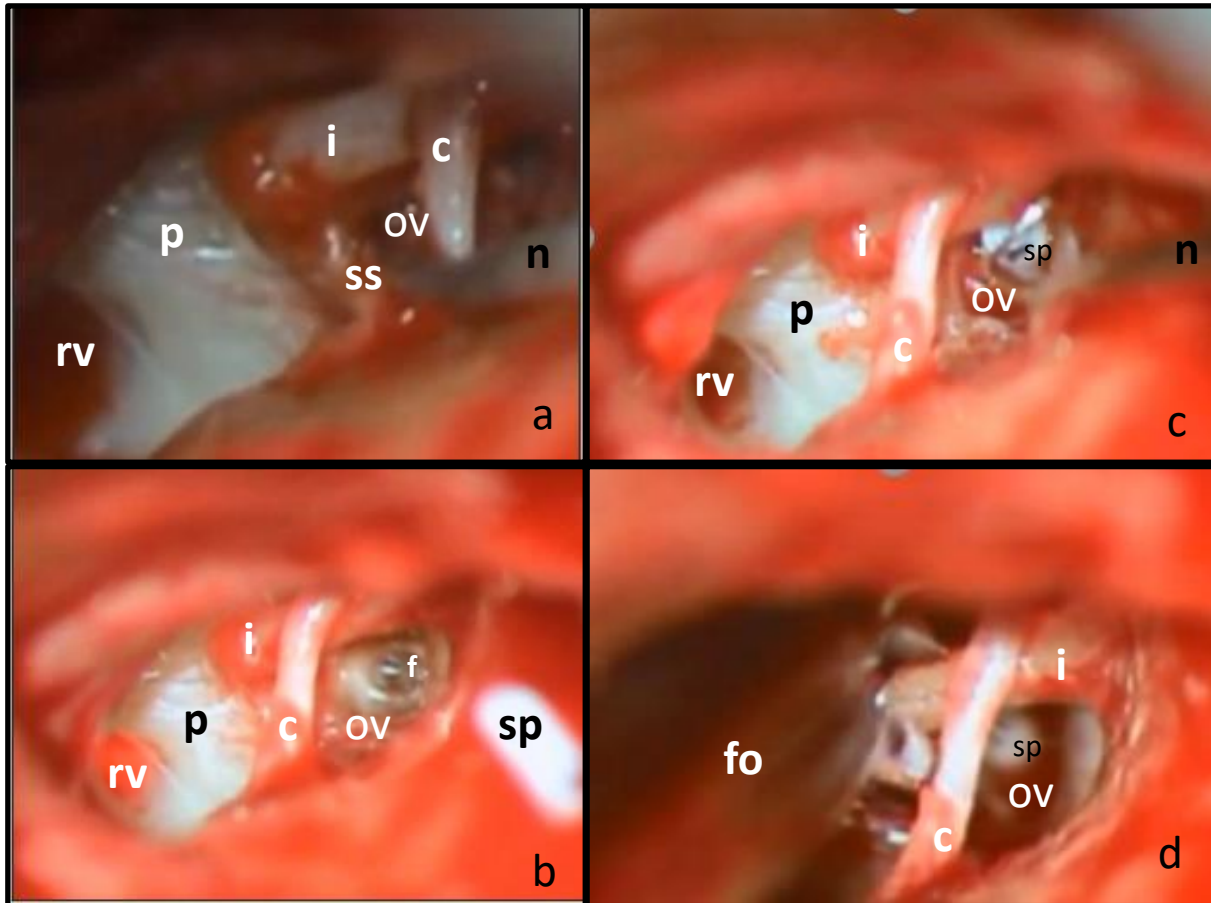
We also hypothesized that scar tissue-related complications are more difficult to correct than other surgical failures.

#### 2.2.5 Hypothesis 5

The level of mechanical stress affecting chorda tympani determinates the severity of taste disturbances after middle ear surgery.

## 2.3 Patients and methods

### 2.3.1 Evaluation of perioperativ IV corticosteroid treatment



**Fig. 3.** Surgical procedure of laser stapedotomy. a, superstructure removal; b, footplate perforation; c, piston insertion; d, crimping of the prosthesis loop

i: incus; p: promontory; rv: round window, ov: oval window; ss: stapes superstructure; c: chorda tympani; n: surgical needle; f: fenestration on oval window; sp: stapes prosthesis; fo: crimping forceps; Own figure.

Eighty-four cases were included in our retrospective study. The surgeries were performed between 2013 and 2018 at the Department of Oto-Rhino-Laryngology, Head and Neck Surgery, Semmelweis University, Budapest. The clinical diagnosis of stapes fixation was made by PTA (pure tone average) testing, tympanometry, stapedius reflex, and physical examination. Surgical indication in our practice depends on multiple factors such as audiological reasons, patient preference, age, middle ear status, bone conduction levels, etc. Because of the Carhart notch effect, the average ABG does not always

represent the extent of the low frequency ABG. The 512Hz tuning fork Rinné negativity could strongly support diagnosis and the decision to operate. Of the 84 patients, 29 were male and 55 were female, with an average age of 46.52 (SD12.09) years. All surgeries were primary CO<sub>2</sub> laser stapedotomies performed with the same standardized surgical technique (fig. 3.). After an endaural approach, the posterior TM (tympanomeatal) flap was elevated, and the stapes fixation was verified by palpation of the ossicular chain. After sharp dissection of the ISJ (incudostapedial joint), the posterior crus of the stapes was vaporized with a CO<sub>2</sub> laser (OPAL L30; TrueScan scanner; Lasram, Budapest, Hungary), and the superstructure was removed in one piece by down-fracturing the anterior crus. Stapedotomy was performed exclusively with the CO<sub>2</sub> laser single-shot vaporization technique (21W, 0.1s). The fenestra diameter was 0.6 mm or 0.8 mm according to the prosthesis diameter (0.4 mm or 0.6 mm, respectively). The prosthesis loop was manually placed and crimped onto the long process of the incus in 83 cases; in one case a malleovestibulopexy was performed. The applied prosthesis diameter was 0.4 mm in 15.5% and 0.6 mm in 84.5% of cases. The majority (85.4%) of the applied pistons were Schuknecht fluoroplastic, stainless, slim shaft wire pistons, diameter 0.6 mm (Gyrus Acmi, USA). Titanium Soft Clip Stapes Pistons, diameter 0.6mm (Kurz, Germany) were used in 6.1%; and Richards Platinum Fluoroplastic Pistons, diameter 0.4mm (Olympus, Japan, (formerly Gyrus)) were applied in 8.5% of cases. The type of prosthesis was selected according to availability.

Concerning the different prosthesis types, we did not suspect any distortions from the use of Soft Clip pistons, since these were used in the same proportion and in a minor number of cases (1 in S, 4 in nS). Most of the surgeries were performed with Richards and Schuknecht type pistons. Both pistons are manufactured by the same company (formerly Gyrus ACMI, acquired by Olympus) and have identical fluoroplastic shafts. Richards is a second-generation piston (fig 2. c); differences between the two designs are in the material and shape of the loop (platinum vs. stainless steel, flat vs. round cross-section respectively). No direct comparison could be found in the literature, but it has been shown that the Schuknecht type piston (fig. 2. d) is not inferior to other second generation pistons and has comparable results [75].

The cases were divided into two groups: in the first group (S), patients received corticosteroid perioperatively (500 mg methylprednisolone IV); the second group (nS)

patients did not receive any corticosteroid perioperatively. The steroid administration was decided before the start of the study on an ad hoc basis. The steroid group ('S', n=23) received 500 mg methylprednisolone IV during the first 2 hours after the beginning of surgery. The control group ('nS', n=61) received no adjuvant therapy. The female-to-male ratio was 14/9 and 41/20; their average ages at the time of surgery were 46.9 (SD 10.5) vs. 46.4 (SD 12.7) years, respectively.

Audiological evaluation was performed with PTA testing according to American Academy of Otolaryngology Head and Neck Surgery (AAO-HNS) guidelines [48]. The average postoperative follow-up time was 175 days (SD 216.8; range 29-1104), which could be considered as a reliable indicator of the long-term results [76]. These data were retrospectively analyzed statistically (IBM SPSS v. 25, Armonk, New York, USA) to define the results of stapedotomies and the effect of corticosteroid treatment. An Independent Samples T Test was used for analyzing group differences, while intervention success was examined with a Paired Samples T test. The statistical significance level was  $p < 0.05$ .

A more detailed methodology can be found in the original publication [77].

### 2.3.2 Evaluation of revision stapedotomies

This retrospective case series study with 23 patients was also carried out at our department. In 13 cases the primary surgery was performed by another department. The reasons behind inadequate results were noted and were classified into two categories. The first category was scar tissue formation-related issues. The second category contained any other surgery-specific problems. Scar tissue formation was considered to be the main reason if it was the only finding during surgery.

The indication for revision was a minimum 10 dB or higher persistent ABG-PTA. The formerly mentioned factors such as audiological reasons, patient preference, age, middle ear status, bone conduction levels, Carhart notch effect, and 512 Hz tuning fork Rinné test were also taken into consideration.



The average time between primary surgery and revision was 749 days (range: 84-11,764). From the 23 cases, 6 patients were male (26%) and 17 were female (74%); the average age was 50.4 (SD 12.0) years. The previously detailed surgical technique was applied in these operations as well. Depending on the intratympanic findings, prosthesis replacement or repositioning was performed, and adhesions were removed mechanically. Malleovestibulopexy had to be performed in five cases.

In one case a stapedectomy was performed; in all other cases the small fenestra technique was preferred. Forty-eight percent (48%) of the applied pistons were Schuknecht fluoroplastic, stainless, slim-shaft wire pistons (Gyrus Acmi, USA); Richards Platinum Fluoroplastic Pistons (Olympus, Japan) were used in 35% of the cases. In the remaining surgeries the original pistons were reapplied (17%).

The cases were divided into subcategories according to reason of failure: Group I: no scar tissue present; Group II.: scar tissue present; Group III.: only scar tissue present. During statistical evaluation Groups II. + III. were tested against Group I. A scar tissue-related complication in our definition means periprosthetic adhesion or inter-perioissicular adhesion (ossicular chain fixation), while surgery-specific failures are LPI necrosis, prosthesis dislocation, ossicular luxation, etc. The cutoff point for follow-up was 3 months at minimum; the average follow-up time was 526 days (SD 521; range 92-1,827). Audiologic work-up was performed according to the same guidelines as before.

Data were analyzed statistically (IBM SPSS v. 25, Armonk, New York, USA) to define descriptive data and the difference between the types of surgical failure. A Bootstrapped Independent Samples t-test was used for analyzing group differences, while intervention success was examined with a Paired Samples t-test. A TOST test with the effect size of '1' was used to determine equivalence and non-inferiority (TIBCO Statistica). The statistical significance level was  $p < 0.05$ .

### 2.3.3 Early postoperative taste disturbance after middle ear surgery

43 surgical cases (15 stapes surgeries, 28 tympanoplasties) were investigated between 2018.01.01. and 2019.02.28. at the Department of Oto-Rhino-Laryngology, Head and Neck Surgery, Semmelweis University, Budapest. Inclusion criteria were the minimum of 18 years of age, and no former middle ear surgery on the investigated side. Average age was 47,3 (19-71) years, male/female ratio was 17/26. Subjective questionnaires were answered by the patients before and one day after surgery. Visual analogue scale and yes or no questions were used to determine the degree of taste disturbances. The level of chorda tympani manipulation during surgery was classified into 5 groups (0 - no manipulation; 1 – nerve has been elevated from the bony groove, no other manipulation; 2 – significant mechanical stress but no visible injury; 3 – visible injury but the continuity intact; 4 – nerve sacrificed). Independent Samples T Test was used for analyzing group differences (TIBCO Statistica TIBCO Software, Palo Alto, CA, USA). Statistical significance level was  $p < 0.05$ . Further details could be found in the original paper [1].

### 3 Results

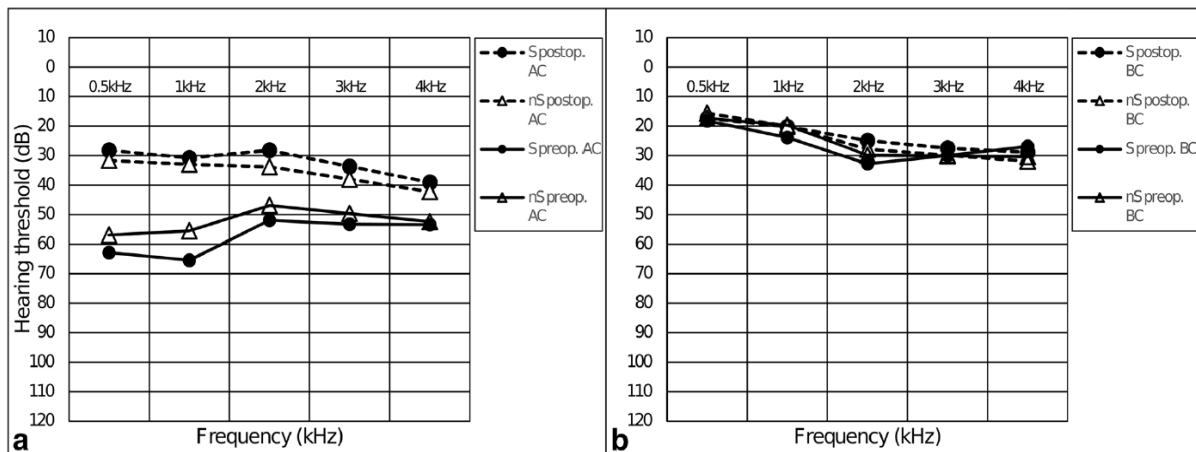
#### 3.1 Mid-term evaluation of perioperative IV corticosteroid treatment efficacy on audiological outcome following CO<sub>2</sub> laser stapedotomy

**Table 1**

Group characteristics of 84 stapes surgery cases [77]

|                                  | Groups          |                 | Significance |    |
|----------------------------------|-----------------|-----------------|--------------|----|
|                                  | S (n=23)        | nS (n=61)       |              |    |
| preop. BC-PTA (dB, mean ± SD)    | 26,19 ± 12,8    | 24,30 ± 10,43   | p=0,491      | ns |
| preop. ABG-PTA (dB, mean ± SD)   | 31,82 ± 8,35    | 28,0 ± 7,98     | p=0,057      | ns |
| preop. AC-PTA (dB, mean ± SD)    | 58,14 ± 17,05   | 52,30 ± 12,77   | p=0,093      | ns |
| age (years, mean ± SD)           | 46,91 ± 10,51   | 46,38 ± 12,70   | p=0,857      | ns |
| follow up time (days, mean ± SD) | 159,08 ± 203,43 | 218,13 ± 248,62 | p=0,268      | ns |
| gender (female/male ratio)       | 1,556           | 2,050           | p=0,586      | ns |
| Piston used                      | Kurz Soft Clip  | 4%              | 7%           |    |
|                                  | Richards        | 22%             | 7%           |    |
|                                  | Schuknecht Wire | 74%             | 87%          |    |

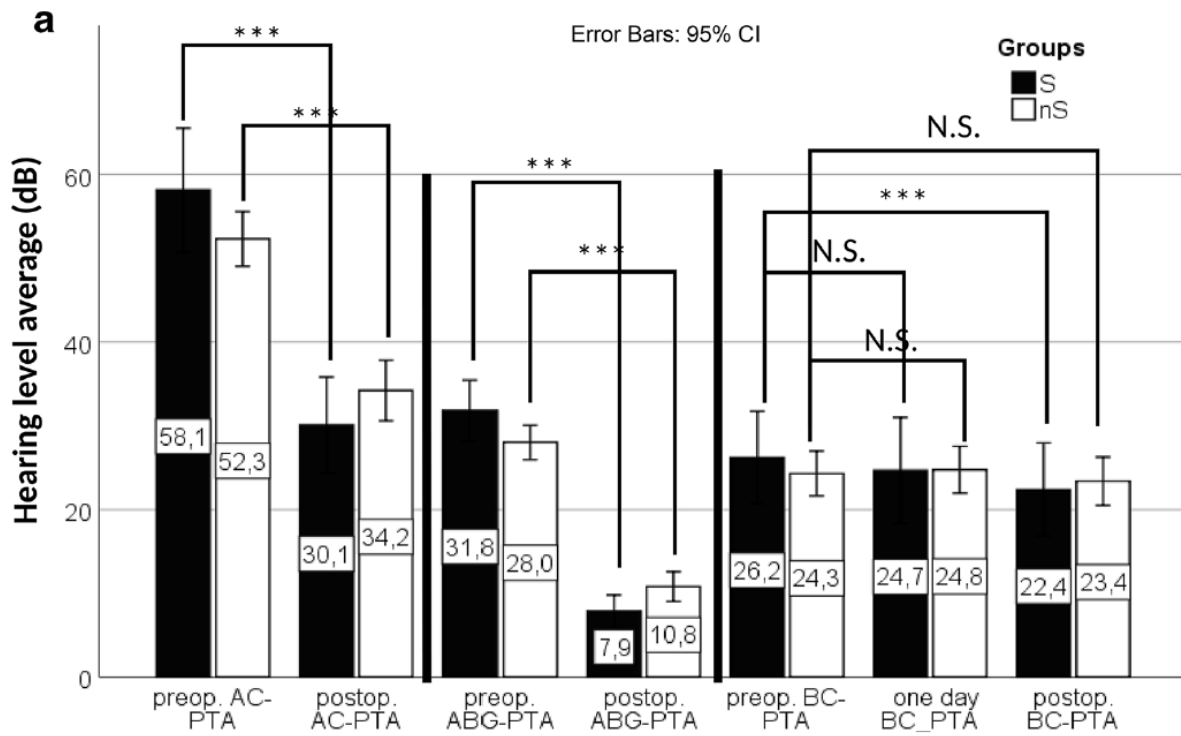
As demonstrated in Table 1, no significant differences could be found in preoperative group characteristics. Looking at the preoperative audiological results, the average hearing thresholds were AC-PTA 53.9 dB (SD 14.2; range: 20.6-95 dB), BC-PTA 24.8 dB (SD 11; range: 5.6-56.9 dB), ABG-PTA 29.05 dB (SD 8.21; range: 12.5-48.1 dB). Eighty-eight percent (88%) of the cases had a 20 dB or higher ABG, and a functional hearing (AC ≤ 30 dB) could only be detected in 2 cases.



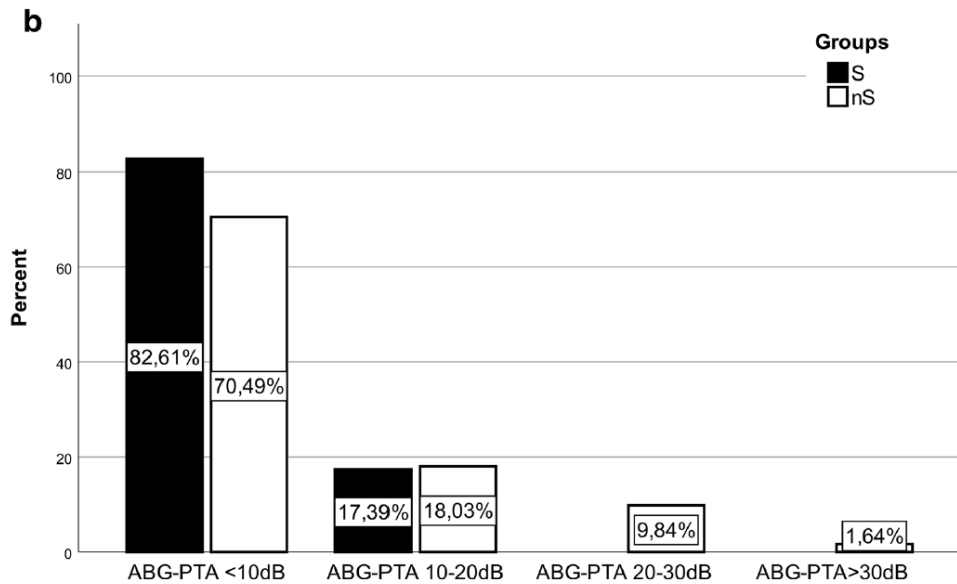
**Fig. 4.** (a.) Pre- and postoperative pure tone audiometry air conduction hearing thresholds. Significant improvement after surgery measured in both groups. (b.) Pre- and postoperative pure tone audiometry bone conduction hearing thresholds. No significant sensorineural hearing loss could be detected. (72)

After the intervention, significant improvement of the hearing levels could be detected in both groups (fig.4.a, fig.5.). The average AC-PTA was 33.07 dB (SD 13.9) after the surgery, and significant air conduction improvement was seen in both groups. S group: 58.14 dB (SD 17.0) vs. 30.08 dB (SD 13.2) ( $p < 0.001$ ); and nS group: 52.31 (SD 12.8) vs. 34.20 dB (SD 14.1) ( $p < 0.001$ ) (fig.4.a; fig5.). ABG closure was also significant in both groups with a mean improvement of 23.9 dB and 17.2 dB, in the S ( $p < 0.001$ ) and nS ( $p < 0.001$ ) groups, respectively (fig. 5). The air-bone gap was closed below 10 dB in 82.6% and 70.5%, and ABG closure between 10-20 dB prevailed 17.4% and 18.0% in the S and nS groups, respectively; 11.5% of the nS group had ABG-PTA >20 dB (fig.6.).

Concerning bone conduction thresholds, the mid-term BC-PTA level showed significant improvement [26.19 dB (SD 12.8) vs. 22.37 dB (SD 12.8);  $p = 0.001$ ] (fig.5.) in the steroid group. Otherwise no significant difference in BC levels could be observed in any comparison in either direction (fig.5.).



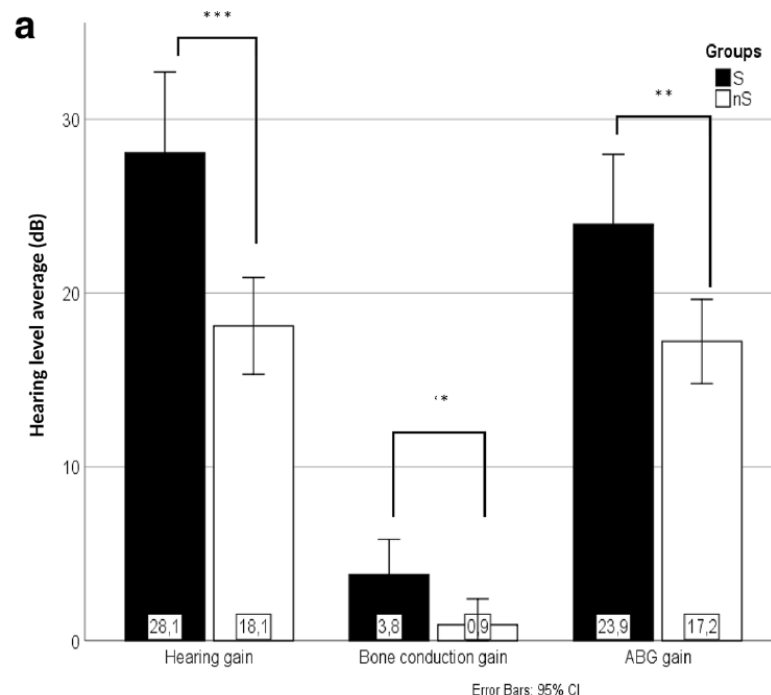
**Fig. 5.** Pure tone average measurements. Evolution of AC, ABG, and BC levels after surgery. (72)



**Fig. 6.** Distribution of postoperative ABG-PTAs of each group in 10 dB bins. Steroid group 100% <20dB ABG; No steroid group 88.5% <20dB ABG (72)

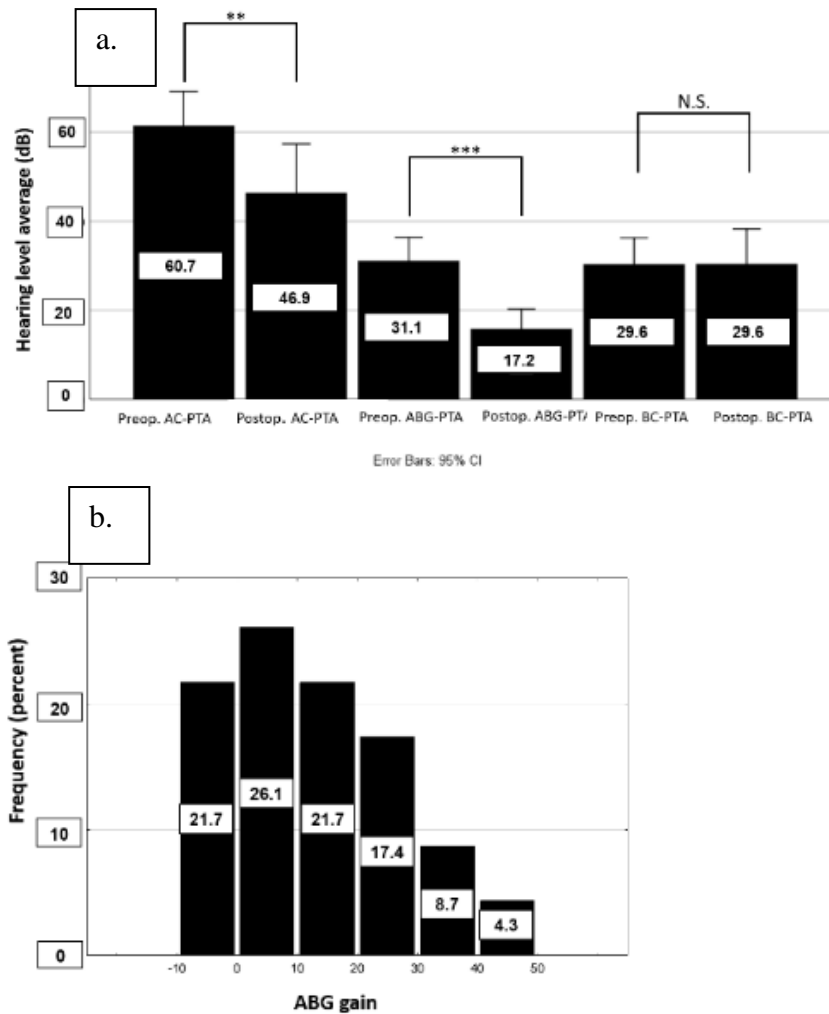
According to these findings, no inner ear damage could be detected during this series in either group, and the intervention was audiological efficient enough to meet literature standards.

In the next step we concentrated on group comparisons. We looked at the hearing gain results which are defined as the difference between preoperative and postoperative AC-PTA. Hearing gain was significantly different across the two groups: 28.1 dB (SD 11.2) in the S group, and 18.1 dB (SD 10.9) in nS. The level of hearing gain could be split into two parts: ABG gain and bone conduction gain, where ABG gain basically represents the improvement in middle ear function, and BC gain represents the change in inner ear function. The difference in ABG gain between the S and nS groups was significant: ( $p=0.005$ ): 23.9 dB (SD 9.8) vs. 17.2 dB (SD 9.5), respectively (fig.7.) And BC gain was also significantly better ( $p=0.038$ ) in the S group: 3.81 dB (SD 4.8) compared to the nS group's 0.92 dB (SD 5.8) (fig. 7.). Overall, we found a significantly positive effect of adjuvant corticosteroid therapy on audiological outcomes, and the positive effect was not only present in bone conduction gain, but mainly in a better ABG closure. This indicates that corticosteroid therapy mainly affects middle ear performance. In our hypothesis, this effect is most likely apparent through the inhibition of scar tissue formation. Following this logic, we tried to discover the significance of postoperative fibrosis in the tympanic cavity.



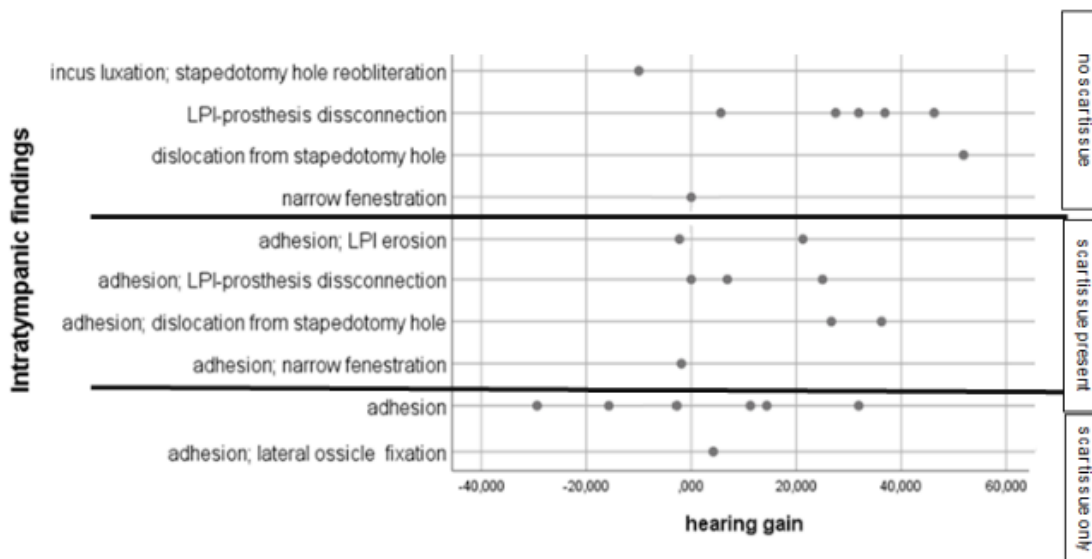
**Fig. 7.** Postoperative audiological improvement is shown across groups concerning hearing gain, ABG gain, and bone conduction gain. (72)

3.2 The role of periprosthetic scar tissue formation in the development of unsatisfactory hearing results after stapedotomy



**Fig. 8.** (a.) Pre-, and post-operative pure tone audiometry AC, ABG, BC hearing thresholds. Significant improvement in AC and ABG levels after revision surgery. (b.) Distribution of ABG gain after revision surgery in 10 dB bins. (73)

AC-PTA significantly improved after revision to 46.9 dB, compared to the 60.7 dB preoperative value ( $p=0.003$ ). Also, significant improvement was seen in ABG-PTA levels after surgical intervention: 17.2 dB vs. 31.1 dB ( $p<0.001$ ). No significant difference could be found between pre- and post-operative BC-PTAs: 29.6 dB vs. 29.6 dB ( $p=0.984$ ) (fig.8.a). The minimum of 10 dB ABG gain was achieved in 52.2% of cases, 10 dB or better ABG closure was found in 43.5% of cases, while ABG closure between 10 and 20dB prevailed in 13% (fig.8.b). These findings indicate that revision surgeries are beneficial to perform even if the results are inferior to those of primary surgeries. The risk of inner ear damage was not significant [78].

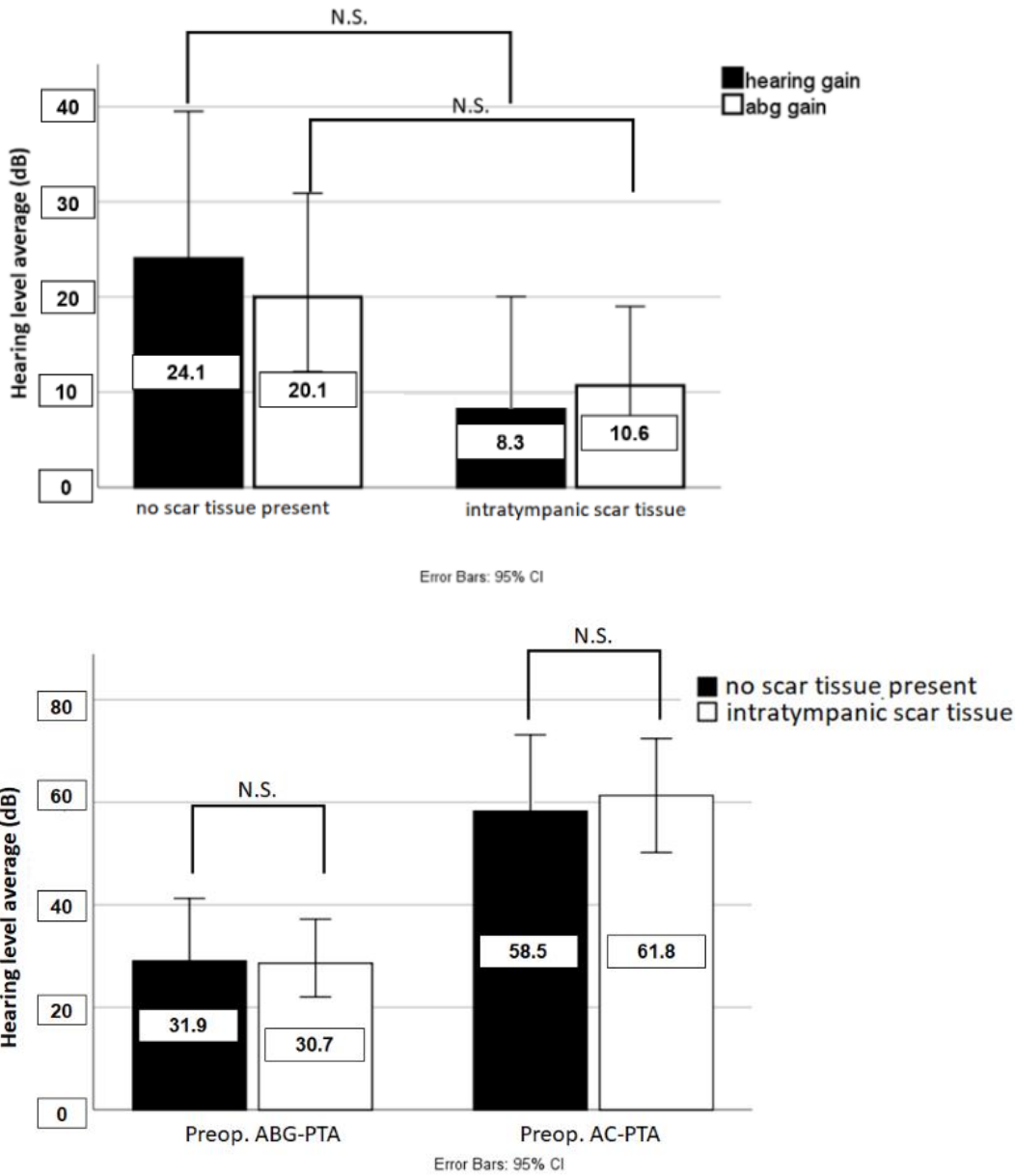


**Fig. 9.** Connection between hearing gain and the intratympanic finding in each revision case. The cases were classified in three groups according intratympanic scar tissue presence (73)

Investigating the frequency of the different problems, periprosthetic adhesion was the most common finding. Adhesions were found in 65% of cases, and in 30% it was the only reason behind compromised results. From the 8 cases where the main problem was scar tissue formation, 6 cases had satisfactory short-term results, followed by progressive hearing loss. In 35% only specific surgical failures were found, while in 35% both types of problems were present (Fig. 9.). The most common specific problem was the disconnection



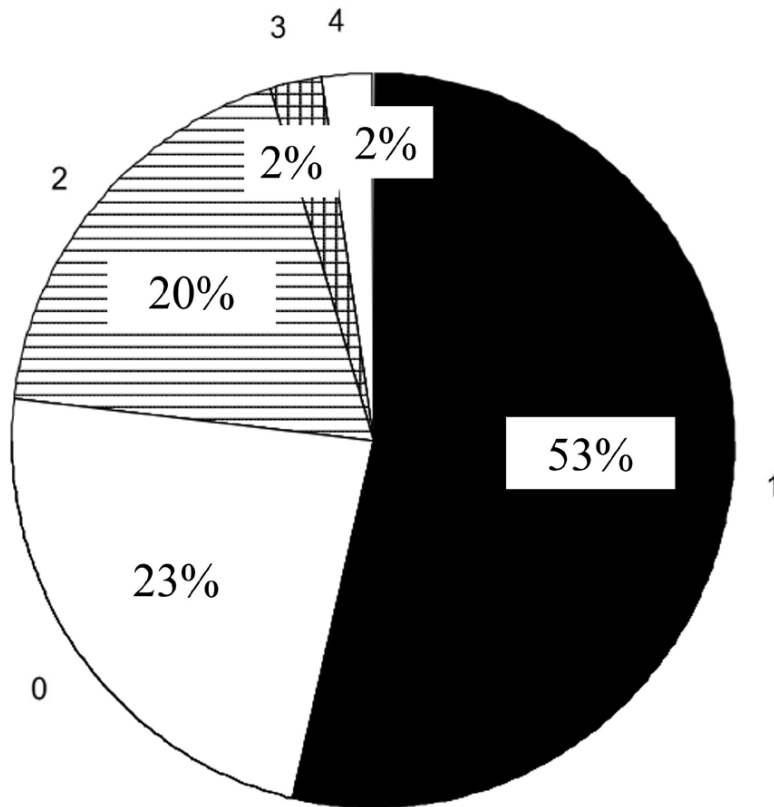
between the piston hook and the long process of the incus. According to figure 9. the highest hearing gains were achieved in these cases.



**Fig. 10.** (a.) ABG and hearing gain differences after revision surgery in case of scar tissue present vs. scar tissue not present. (b.) ABG and AC PTA levels after primary stapes surgery, scar tissue present vs. scar tissue not present (73)

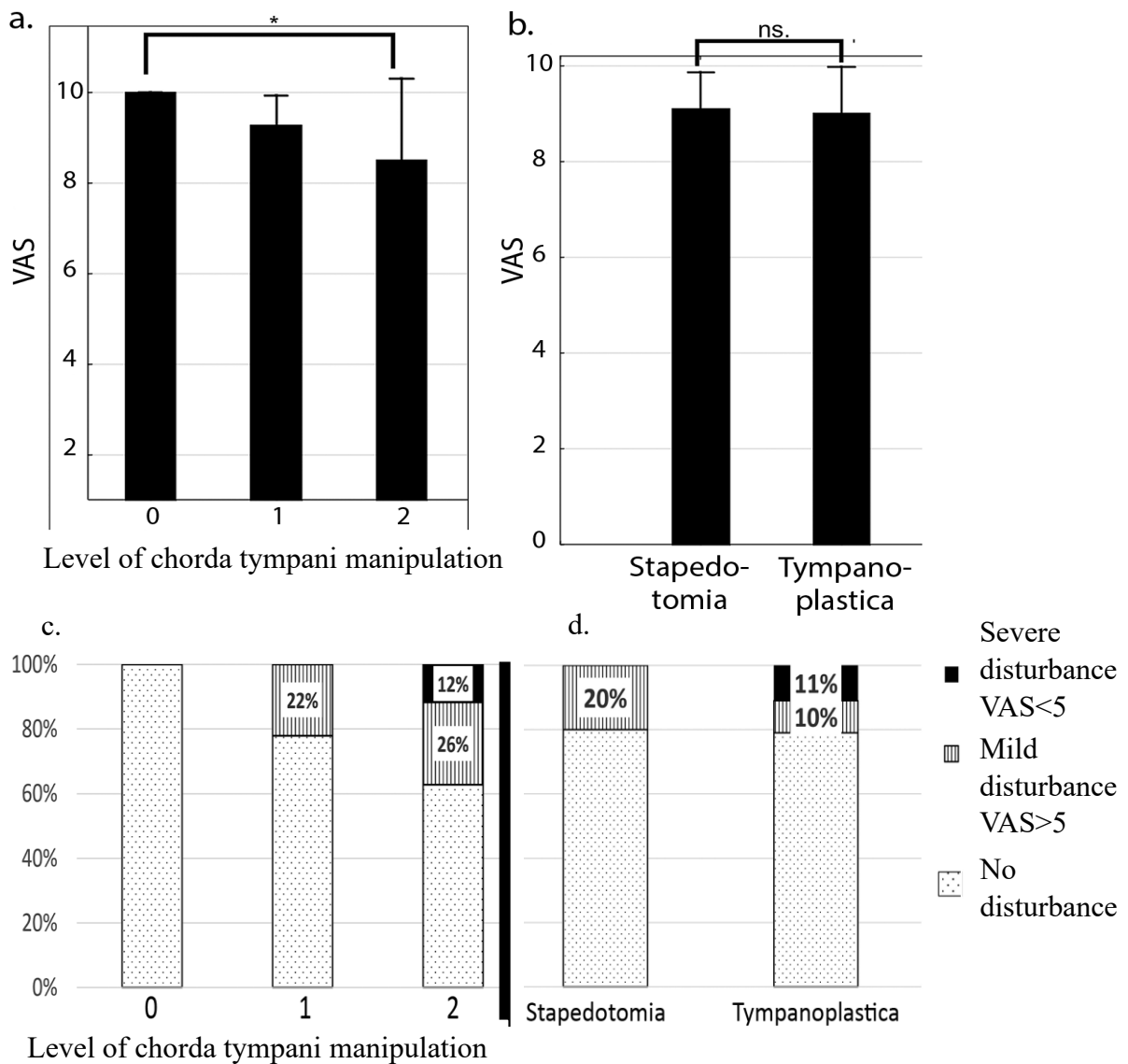
In the last part we examined the role of scar tissue presence in the middle ear on hearing results. In the presence of intratympanic adhesions, ABG gain and hearing gain were inferior compared to all other cases, however the difference was not significant statistically (fig. 10.a;  $p=0.075$ ;  $p=0.121$ ). Considering these findings, we performed TOST testing to determine whether scar tissue formation has the equivalent detrimental impact on hearing outcomes as other non-adhesion associated failures. Looking at ABG gain and hearing gain values, equivalence between the two groups was rejected. At the same time, non-inferiority of the intratympanic fibrosis-associated negative effect was shown compared to the other group ( $p=0.962$  upper tailed;  $p=0.037$  lower tailed; and  $p=0.919$ ;  $p=0.044$  respectively). No statistically significant difference between preoperative (after primary stapes surgery) ABG and AC PTA levels across the ‘scar tissue’ and ‘no scar tissue’ groups (fig.10.b) ( $p=0.826$  and  $p=0.692$  respectively) could be found.

### 3.3 Early postoperative taste disturbance after middle ear surgery



**Fig. 11.** Frequency of different levels of chorda tympani manipulation: 0 - no manipulation; 1 – nerve has been elevated from the bony groove, no other manipulation; 2 – significant mechanical stress but no visible injury; 3 – visible injury but the continuity intact; 4 – nerve sacrificed [1]

From the 43 surgeries, we had to sacrifice the nerve in one case, and in one other case visible injury occurred) (fig. 11.). In these cases, postoperative VAS score was 7/10 and 2/10 respectively. Concerning groups ‘0’, ‘1’ and ‘2’ postoperative VAS scores were 10, 9.26 and 8.5 respectively (10- no taste disturbance, 0 maximal taste disturbance). Between group 0 and 2 significant difference was found ( $p=0.039$ ). Between other groups there was no significant difference (fig.12.a.). In cases when only the tympanomeatal flap was elevated we found no taste disturbance, when the nerve was also elevated to perform lateral atticotomy, disturbances were seen in 22%, while in cases of further manipulation disturbances were registered in 38% of cases (fig.12. c.). Comparing stapedotomy and tympanoplasty results, VAS scores were 9 and 9.1. There was no significant difference between these groups ( $p=0.861$ ) (fig.12. b.). In the stapes surgery group tasting problems



**Fig. 12.** Postoperative tasting on VAS scale (a.) depending on the level of nerve manipulation, (b.) depending on the type of surgery; Frequency of taste disturbances (c.) depending on the level of nerve manipulation, (d.) depending on the type of surgery [1]

were found in 20%, while in the tympanoplasty group this number was 21% (Fig. 12. d.). Severe disturbance was only seen in the tympanoplasty group.

## 4 Discussion

According to our investigations, CO<sub>2</sub> laser stapedotomy was found to be an efficient and atraumatic technique, with high success rates and an undetectable decrease in inner ear function after surgery. This observation is in correspondence with literature data, reinforcing the utilization and good efficacy of this method in our own setting.

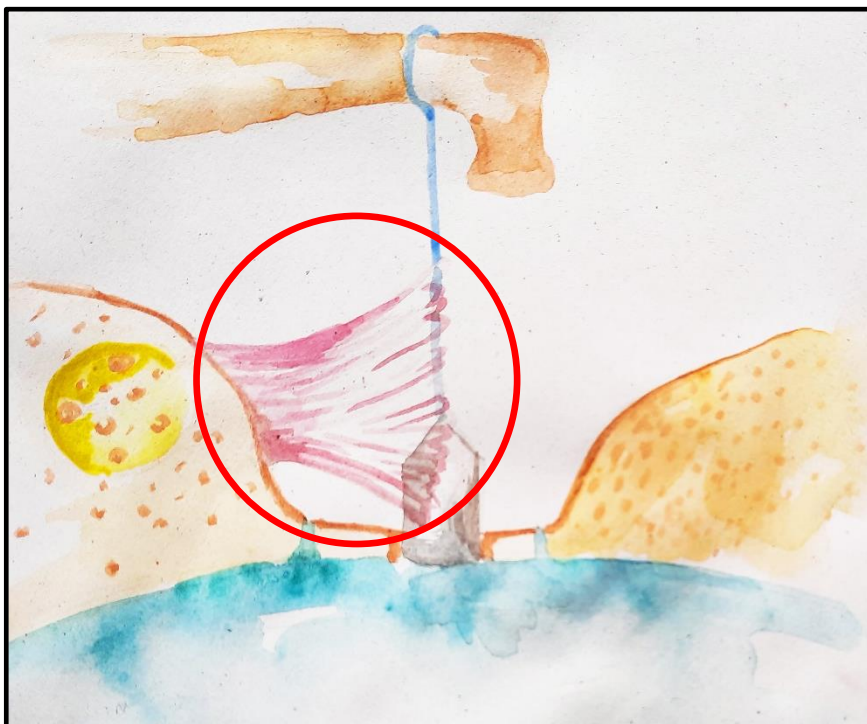
Looking at the results with adjuvant corticosteroid therapy, although no sensorineural hearing loss was detected in the series, the S group exhibited better audiological measurements compared to the control group. The S group had significantly better results in hearing gain, ABG gain, and BC gain values. According to the 20 dB average AC improvement in stapes surgery, the 2.9 dB (14.5%) BC gain and 6.7dB (33.5%) ABG-gain must be interpreted as being clinically relevant. Looking at the detailed data, it is apparent and surprising that the main reason behind the better performance of the S group is the higher ABG gain. ABG gain and BC are the two components of hearing gain, where ABG gain represents the improvement in middle ear function. While at the start of the research the beneficial effects of corticosteroids were expected to be connected with the improvement of inner ear function, it appears that they could be more related to middle ear function. In conclusion, perioperative corticosteroid therapy has a positive effect on hearing outcomes, affecting not only sensorineural thresholds, but primarily through its contribution to a better ABG closure.

These findings raise many questions. The role of perioperative corticosteroids in stapes surgery is not clear, and data in the literature is limited. Our results are in contrast with some previous publications [64, 65], however the cochleoprotective effect of these drugs has already been demonstrated in cases of acute inner ear injury, during otologic surgical procedures, and in non-human laboratory studies as well [65, 66, 68, 69, 79]. The beneficial effect of methylprednisolone on BC gain is in agreement with the latter literature. Interestingly, the major outcome of the adjuvant therapy was the improvement in middle ear function, which is a completely new observation. Considering the different physiological effects of methylprednisolone, there are possible explanations for this phenomenon.

Middle ear function after stapes surgery depends on multiple factors. A primary factor is ossicular chain mobility, which could be compromised because of prosthesis-related problems or general middle ear problems. General problems could be tympanic membrane damage or Eustachian tube dysfunction leading to ineffective middle ear ventilation and decreased function, which are extremely rare in stapes surgery. The function of the prosthesis could be inadequate due to surgical mistakes or prosthesis-related problems. These include improper fenestration, LPI necrosis, LPI-prosthesis disconnection, periprosthetic adhesion, incorrect sizing, etc. In our experience and according to other authors, the presence of various types of adhesions is considered relatively common in revision stapes surgery [72].

Looking at the effect of corticosteroids it is important to note that methylprednisolone has a dose-dependent inhibitory effect on granulation tissue formation [80], and that corticosteroids have a beneficial effect on adhesive inflammations by decreasing the amount of vascular hyperplasia and fibrosis [81]. Corticosteroids not only passively attenuate inflammation by suppressing monocytes and macrophages, but the CS-stimulated naïve monocytes actively coordinate the resolution of inflammatory processes [82].

Summarizing these data, it is most likely that the better ABG closure we found is the consequence of a lower scar tissue formation rate in the tympanic cavity attributable to methylprednisolone therapy (fig.13.). Even the inhibition of minor adhesions, which otherwise do not require revision, could help to achieve better hearing gain.



**Fig. 13.** The estimated place of action of corticosteroid adjuvant therapy. Own figure

Corticosteroids have been already used in different surgical disciplines to control postoperative fibrosis in the surgical field. Triamcinolone decreases postoperative fibrin formation after cataract surgery [83]. Methylprednisolone prevents epidural fibrosis [84] and cauda equina adhesions [85] after neurosurgical procedures, while also having a positive impact on postoperative pericardial adhesion formation [86].

These data consolidate the idea that the role of corticosteroids in improving middle ear function after stapedotomy, via decreasing postsurgical inflammation and adhesion formation, is significant.

Of course, the study has its limitations. The average postoperative follow-up of less than one year could exclude long-term complications like incus necrosis or prosthesis dislocation. However, no effect of corticosteroid treatment is anticipated concerning these conditions, therefore this circumstance has no distortional influence. Although the group characteristics were statistically not different, the patients were selected on an ad hoc basis, which could lead to potential selection bias. The data represent the results of a single institution and a single surgeon. Evaluation is based on subjective hearing tests, however pure-tone audiometry is considered to be the gold standard for measuring hearing outcomes after stapes surgery.

Further investigation is necessary to clarify these findings and questions. The method of administration could be an area for improvement. The single dose treatment with methylprednisolone is a relatively risk-free solution, but to lower the chance of any undesired effect, topical administration could be an even more effective method. Furthermore, higher intracochlear and intratympanic concentrations could be achieved. Topical intratympanic administration during surgery can be considered as a noninvasive procedure, considering the wide access to the tympanic cavity after TM flap elevation. Intracochlear drug administration could be more complicated and invasive, but with the possibility of drug-eluting prosthesis, it will be available non-invasively in the future. A more precise topical drug delivery with an elongated delivery time could be achieved with the development of drug-eluting prosthesis. With this currently theoretical solution, it would be possible to allocate the desired amount of the drug selectively into the cochlea or into the middle ear around the piston. The drug-eluting polymer could be applied anywhere on the piston according to the desired application site.

This solution would not only be suitable for corticosteroid application but for other drugs which require more precise application to this area as well. Such an idea could be the selective intracochlear application of bisphosphonates to cure active otosclerosis. Other pharmaceutical agents could also be tested.

To achieve a deeper understanding of this topic, the frequency and role of the most common reasons for decreasing hearing results need to become known, with special regard to intratympanic adhesions. Since some of these complications cannot be seen in clinical imaging studies, investigation through the results of revision surgeries may be the best option available.

Following this logic, we analyzed some of revision cases to obtain answers to these presumptions. Revision surgeries were found to be a valuable treatment option in cases of inadequate results after primary surgery. At the same time, the interventions were safe in that they did not cause further sensorineural hearing loss. However, the results were inferior compared to primary surgeries, as is already known according to the literature. That result underlines the importance of optimal surgical performance during first surgeries and the importance of discovering the most significant reasons behind failures.

In our study, the leading reason causing a mechanical problem in middle ear was the presence of intratympanic adhesions. In our definition, adhesion is an intratympanic scar tissue formation, considered to be a fibrotic non-anatomical connection between two tissue planes induced by injury. This intratympanic scar tissue formation had the same negative effect on audiological results as all the other failure types after primary surgery. This negative effect was present in the form of ABG formation, representing middle ear disfunction, and it was the most common adverse finding in the tympanic cavity. The former observations mean that even in the era of modern atraumatic stapes surgery, intraoperative injury and consequent scar tissue formation is a leading cause of compromised hearing results.

In investigating the influence of intratympanic scarring on the outcome of revision surgeries, according to our data the negative effect of adhesion formation is not inferior to the negative effect of specific surgical failures in terms of hearing results. In other words, in the presence of intratympanic adhesions, the audiological results were not superior compared to the remaining cases. This means that the correction of scar tissue-related problems is at least as difficult as the correction of the other problems. A similar



observation about the difficulty of dealing with intratympanic adhesions has already been presented in the literature [71]. This observation underlines the importance of an atraumatic first surgery, because surgery-induced scarring seems to have a detrimental effect not only on primary results but on the results of following surgeries as well. Due to the retrospective setting and the low number of cases, the statistical power of this study is limited, which could explain why no statistical difference, but non-inferiority was demonstrated.

The results underline the importance of applying the most atraumatic surgical technique, the preservation of intact intratympanic mucosa, and the prevention of post-surgical scar tissue formation. The assumption is also reinforced that the corticosteroid-related increased ABG gain efficiency could be caused by the decrease in intratympanic scarring.

Besides the possible beneficial effect of adjuvant pharmaceutical therapy described above, there are further technical advancements which could help in performing interventions in the least traumatic way. These include laser techniques, heat crimping pistons, or the adequate use of endoscopes in middle ear surgery. However, much experience and deep surgical knowledge is unavoidably necessary to perform stapes surgery at such a high level. The appropriate experience and surgical instruments are a must for good results, and the operation should be performed under the supervision of experienced surgeons [87].

Taste disturbance after middle ear surgery is a common complication[73], thus it is necessary to investigate this problem to provide enough knowledge for intraoperative decision making and for patients education as well. In our series it was demonstrated that with proper surgical technique chorda tympani nerve could be spared in the vast majority of cases. In cases of intact chorda tympani nerve, we found significant connection between the level of manipulation and the degree of taste disturbance. However, these disturbances were not as severe as in cases with visible injury to the nerve. When the nerve was elevated from its bony sulcus, but no other manipulation was made only mild complaints were registered. This means, that this step, which is one the fundamental steps during stapes surgery, does not cause taste disturbance on its own.

Postoperative dysgeusia after middle ear surgery fortunately, has fine healing rates during the first six months. In cases with minimal mechanical manipulation this rate is around 61-

90%, in cases of mechanical injury it is around 79-85%, even if the nerve is sacrificed the healing rate is around 61% [88, 89]. Preserving chorda tympani in case of injury is topic of debate. In our cases after 3 weeks the patient with injured but continuous nerve had 3/10 taste sensation, while the patient with sacrificed nerve had 10/10. According to this, and to similar findings in the literature [88, 90] it is advisable to sacrifice injured nerve to achieve better postoperative quality of life. However, it is important to underline that this scenario only applies when the injury is severe. As it was demonstrated above, mechanical traumas without visible injury to nerve won't cause considerable taste disturbances.

We did not find any connection between surgery type and the level of taste disturbances. All in all, it looks like the most important factor is not the type of intervention but the level of manipulation on the nerve, determining the level of postoperative dysgeusia. Surgeries when controlled manipulation happens with chorda tympani are safe, however nerve transection could be a better option compared to leaving the severely injured nerve behind.

## 5 Conclusions

Middle ear surgery has a long history with a constant evolution which has proceeded progressively more quickly in recent decades. Thanks to this progress, otologic surgery is at a very high standard today. Stapes surgery is a special breed of middle ear surgery where the only goal is function gain. Standards and dangers are even higher compared to other interventions.

In our research we have been investigating the possibility of refining stapedotomy operative techniques to optimise audiological efficacy. It was shown that CO<sub>2</sub> laser stapedotomy is an efficient technique causing no detectable sensorineural hearing loss. The use of adjuvant methylprednisolone therapy further improves audiological outcomes. This impact is, unexpectedly, not only the consequence of better sensorineural hearing but it is mainly caused by better middle ear performance, which is most likely due to the scar formation inhibitory effect of corticosteroids, as the major reason behind compromised conductive hearing levels after stapedotomy is intratympanic adhesion formation. This problem is not only the leading cause behind compromised results, but the correction is difficult during revision. Nonetheless, revision stapedotomy is valuable and a safe surgery to perform, even if the results are inferior to those from primary surgeries.

According to our results, we highly recommend the use of CO<sub>2</sub> laser stapedotomy combined with adjuvant corticosteroid therapy. This method seems to optimise audiological outcomes. At the same time, it is equally important to perform the surgery with adequate experience and technique, as not only inner ear traumas but also minor traumas to the middle ear mucosa could compromise the results.

The use of corticosteroids must be investigated further to clarify their exact role. The application of adjuvant therapy could be done topically as well. This is one of the latest innovations in our practice. A new prospective, controlled, randomized study is in progress to seek answers to questions about the efficacy of different administration methods.

Further developments based on these conclusions could be the introduction of drug-eluting prostheses. This could be a more precise tool for applying pharmaceutical therapies in the middle ear. This possibility would not only be useful in stapes surgery and corticosteroid administration, but could also be applied in other otologic surgical procedures.

The difficulty of revision stapedotomies is well understood in the literature, however due to the nature and indication of this procedure the number of available cases is limited, even in otologic centres. To better clarify our results, a systematic review of revision cases could be helpful in understanding indications and to specify expectations towards this intervention. Our group is running a review concerning these questions as well.

Overall, we have investigated questions in stapes surgery, which had limited data available in the literature regarding revision surgery results and adjuvant pharmaceutical therapy. Concerning adjuvant corticosteroid therapy, we were the first to describe its significant effect on conductive hearing performance. The rationale of this finding is most likely the scar tissue-decreasing effects of methylprednisolone. The background of this initially surprising result was further investigated in our practice. During this second part of the research, the findings reinforced the explanation we had proposed for this observation. In order to further understand the details of this topic and to confirm these findings, additional studies are underway in our group.

Chorda tympani related postoperative taste disturbance is a well known phenomenon after middle ear surgery. With proper surgical technique the nerve could be spared in most of the cases, and controlled manipulation with nerve is safe during stapes surgery and other middle ear surgeries as well. The most important factor determining complications is the level of mechanical stress, the type of surgery won't prognosticate the chance of taste disturbance. The consolidation of dysgeusia is looking better in case of transection compared to severe injury, thus sacrificing the nerve could be a viable option if the injury is severe. This information could be useful during patient education and intraoperatively as well.

## 6 Summary

The aim of our research is to contribute to the progress of middle ear and especially stapes surgery. Our special focus was the optimisation of audiological results. We performed investigations concerning CO<sub>2</sub> laser stapedotomy, perioperative corticosteroid therapy, and revision stapes surgery to understand the reason behind compromised results, and to clarify the roles of these methods. Chorda tympani related postoperative dysgeusia was also investigated. Two retrospective and one prospective studies were run on these topics. The hypotheses were the following:

1. CO<sub>2</sub> laser is an atraumatic solution for performing stapedotomy, thus adequate ABG and hearing gains could be achieved while causing no decrease in sensorineural hearing function.
  2. Perioperatively administered IV methylprednisolone therapy could have a protective effect against minor intraoperative inner ear damage in cases of CO<sub>2</sub> stapedotomies. Therefore, audiological results could be superior to the control group.
  3. Inflammation induced by surgery and consequent scar tissue formation in the tympanic cavity could be the major reason behind compromised ABG gain.
  4. Scar tissue-related complications are more difficult to correct compared to other surgical failures during revision surgeries.
  5. The level of mechanical stress affecting chorda tympani determinates severity of taste disturbances after middle ear surgery.
- We have found that CO<sub>2</sub> laser stapes surgery is an efficient and safe method.
  - The administration of perioperative methylprednisolone contributed to better hearing results after stapes surgery. However, this contribution was mainly achieved through better conductive thresholds and to a lesser extent through elevated sensorineural thresholds.
  - Intratympanic scar tissue formation was the major reason behind inadequate results after stapes surgery according to our series.
  - Scar tissue-related failures are at least as difficult to correct as any other surgery-specific complication in stapes surgery.
  - The most important factor is not the type of intervention but the level of manipulation on the nerve, determining the level of postoperative dysgeusia.



## 7 References

1. Székely, L., A. Gáborján, L. Tamás, and G. Polony, Korai posztoperatív ízérzészavar középfülsebészeti beavatkozásokat követően. *Orvosi Hetilap*, 2022. 163(23): p. 920-925.
2. Sarkar, S., A review on the history of tympanoplasty. *Indian J Otolaryngol Head Neck Surg*, 2013. 65(Suppl 3): p. 455-460.
3. Bento, R.F. and A.C. Fonseca, A brief history of mastoidectomy. *Int Arch Otorhinolaryngol*, 2013. 17(2): p. 168-178.
4. Riolan, J., A sure guide, or, The best and nearest way to physick and chyrurgery [Encheiridium anatomicum et pathologicum]. 1671: John Streater London.
5. Louis, A., Extraits de l'eloge de Jean-Louis Petit lus dans la seance publique de l'Academie royale de chirurgie du 26 mai 1750 par A. Louis. *Chirurgie*, 2001. 126(475).
6. Schmucker, J., *Vermischte Chirurgische Schriften*. vol. 3. Berlin; 1782.
7. Toynbee, J., *On the use of an artificial membrane Qmpaniin cases of deafness dependent upon perforations or destruction of the natural organ*. London: J Churchill & Sons; 1853.
8. Wilde, W., *Aural surgery*. 1853: Dublin.
9. Kessel, J., Über die Durchschneidung des Steigbügel Muskels beim Menschen und über die Extraction des Steigbügels resp. der Columella bei Thieren. *Arch Ohrenheilkd*, 1876(11): p. 199-217.
10. Jack, F.L., *Remarkable improvement in hearing by removal of the stapes*. 2020: Hansebooks GmbH.

11. Häusler, R., General history of stapedectomy. *Adv Otorhinolaryngol*, 2007. 65: p. 1-5.
12. Berthold, E., Uebermyringoplastik. *Wier Med Bull*. 1878;1:627.
13. Wullstein, H., The restoration of the function of the middle ear, in chronic otitis media. *Ann Otol Rhinol Laryngol*, 1956. 65(4): p. 1021-1041.
14. Valsalva, A., *The human ear (Latin)* Bononiae: C. Pisarri.
15. Mudry, A., Adam Politzer (1835-1920) and the Description of Otosclerosis. *Otology & Neurotology*, 2006. 27(2): p. 276-281.
16. Sourdille, M., New technique in the surgical treatment of severe and progressive deafness from otosclerosis. *Bulletin of the New York Academy of Medicine*, 1937. 13(12): p. 673.
17. Lempert, J., Improvement of hearing in cases of otosclerosis: a new, one stage surgical technic. *Archives of Otolaryngology*, 1938. 28(1): p. 42-97.
18. Rosen, S. and M. Bergman, Simple Method for Restoring Hearingl in Otosclerosis Mobilization of Stapes. *Acta oto-laryngologica*, 1954. 44(1): p. 78-88.
19. Shea, J.J., Jr., Fenestration of the oval window. *Ann Otol Rhinol Laryngol*, 1958. 67(4): p. 932-951.
20. Cheng, H.C.S., S.K. Agrawal, and L.S. Parnes, Stapedectomy Versus Stapedotomy. *Otolaryngol Clin North Am*, 2018. 51(2): p. 375-392.
21. Perkins, R.C., Laser stapedotomy for otosclerosis. *The Laryngoscope*, 1980. 90(2): p. 228-241.



22. Fang, L., H. Lin, T.Y. Zhang, and J. Tan, Laser versus non-laser stapedotomy in otosclerosis: a systematic review and meta-analysis. *Auris Nasus Larynx*, 2014. 41(4): p. 337-342.
23. Kamalski, D.M., R.M. Verdaasdonk, T. de Boorder, R. Vincent, H. Versnel, and W. Grolman, Comparing mechanical effects and sound production of KTP, thulium, and CO2 laser in stapedotomy. *Otol Neurotol*, 2014. 35(7): p. 1156-1162.
24. Schuknecht, H.F., Film: Stapedectomy and graft-prosthesis operation. *Acta otolaryngologica*, 1960. 51(3-4): p. 241-243.
25. Wengen, D.F.A., A new self-retaining titanium clip stapes prosthesis. *Adv Otorhinolaryngol*, 2007. 65: p. 184-189.
26. Knox, G.W. and H. Reitan, Shape-memory stapes prosthesis for otosclerosis surgery. *Laryngoscope*, 2005. 115(8): p. 1340-1346.
27. McManus, L.J., P.J. Dawes, and M.D. Stringer, Surgical anatomy of the chorda tympani: a micro-CT study. *Surg Radiol Anat*, 2012. 34(6): p. 513-8.
28. Wang, P.C., S.N. Merchant, M.J. McKenna, R.J. Glynn, and J.B. Nadol, Jr., Does otosclerosis occur only in the temporal bone? *Am J Otol*, 1999. 20(2): p. 162-165.
29. Causse, J.R. and J.B. Causse, Otospongiosis as a genetic disease. Early detection, medical management, and prevention. *Am J Otol*, 1984. 5(3): p. 211-223.
30. McKenna, M.J. and B.G. Mills, Immunohistochemical evidence of measles virus antigens in active otosclerosis. *Otolaryngol Head Neck Surg*, 1989. 101(4): p. 415-421.
31. Schrauwen, I. and G. Van Camp, The etiology of otosclerosis: a combination of genes and environment. *Laryngoscope*, 2010. 120(6): p. 1195-1202.

32. Macielak, R.J., J.P. Marinelli, D.J. Totten, C.M. Lohse, B.R. Grossardt, and M.L. Carlson, Pregnancy, Estrogen Exposure, and the Development of Otosclerosis: A Case-Control Study of 1196 Women. *Otolaryngol Head Neck Surg*, 2021. 164(6): p. 1294-1298.
33. Lippy, W.H., L.P. Berenholz, A.G. Schuring, and J.M. Burkey, Does pregnancy affect otosclerosis? *Laryngoscope*, 2005. 115(10): p. 1833-1836.
34. Schuknecht, H.F. and W. Barber, Histologic variants in otosclerosis. *Laryngoscope*, 1985. 95(11): p. 1307-1317.
35. Bretlau, P., Relation of the otosclerotic focus to the fissula ante-fenestram. *J Laryngol Otol*, 1969. 83(12): p. 1185-1193.
36. Danesh, A.A., N. Shahnaz, and J.W. Hall, 3rd, The Audiology of Otosclerosis. *Otolaryngol Clin North Am*, 2018. 51(2): p. 327-342.
37. Ishai, R., C.F. Halpin, J.J. Shin, M.J. McKenna, and A.M. Quesnel, Long-term Incidence and Degree of Sensorineural Hearing Loss in Otosclerosis. *Otol Neurotol*, 2016. 37(10): p. 1489-1496.
38. Quesnel, A.M., R. Ishai, and M.J. McKenna, Otosclerosis: Temporal Bone Pathology. *Otolaryngol Clin North Am*, 2018. 51(2): p. 291-303.
39. Doherty, J.K. and F.H.J. Linthicum, Spiral Ligament and Stria Vascularis Changes in Cochlear Otosclerosis: Effect on Hearing Level. *Otology & Neurotology*, 2004. 25(4): p. 457-464.
40. Nelson, E.G. and R. Hinojosa, Questioning the relationship between cochlear otosclerosis and sensorineural hearing loss: a quantitative evaluation of cochlear structures in cases of otosclerosis and review of the literature. *Laryngoscope*, 2004. 114(7): p. 1214-1230.

41. Shahnaz, N. and L. Polka, Standard and multifrequency tympanometry in normal and otosclerotic ears. *Ear Hear*, 1997. 18(4): p. 326-341.
42. Pearson, R.D., L.T. Kurland, and D.T. Cody, Incidence of diagnosed clinical otosclerosis. *Arch Otolaryngol*, 1974. 99(4): p. 288-291.
43. Sakihara, Y. and A. Parving, Clinical otosclerosis, prevalence estimates and spontaneous progress. *Acta Otolaryngol*, 1999. 119(4): p. 468-472.
44. Stromback, K., L. Lundman, A. Bjorsne, J. Grendin, A. Stjernquist-Desatnik, and Y. Dahlin-Redfors, Stapes surgery in Sweden: evaluation of a national-based register. *Eur Arch Otorhinolaryngol*, 2017. 274(6): p. 2421-2427.
45. Lippy, W.H., L.P. Berenholz, and J.M. Burkey, Otosclerosis in the 1960s, 1970s, 1980s, and 1990s. *The Laryngoscope*, 1999. 109(8): p. 1307-1309.
46. Crompton, M., B.A. Cadge, J.L. Ziff, A.J. Mowat, R. Nash, J.A. Lavy, H.R.F. Powell, C.P. Aldren, S.R. Saeed, and S.J. Dawson, The Epidemiology of Otosclerosis in a British Cohort. *Otol Neurotol*, 2019. 40(1): p. 22-30.
47. Vincent, R., N.M. Sperling, J. Oates, and M. Jindal, Surgical findings and long-term hearing results in 3,050 stapedotomies for primary otosclerosis: a prospective study with the otology-neurotology database. *Otol Neurotol*, 2006. 27(8 Suppl 2): p. S25-47.
48. Committee on Hearing and Equilibrium guidelines for the evaluation of results of treatment of conductive hearing loss. American Academy of Otolaryngology-Head and Neck Surgery Foundation, Inc. *Otolaryngol Head Neck Surg*, 1995. 113(3): p. 186-187.
49. Antonelli, P.J., Prevention and Management of Complications in Otosclerosis Surgery. *Otolaryngol Clin North Am*, 2018. 51(2): p. 453-462.

50. Hamerschmidt, R., S.S. Saab, B. Carvalho, and C.D. Carmo, Short-Term Audiological Results of Diode Laser in Comparison with Manual Perforation in Stapes Surgery. *Int Arch Otorhinolaryngol*, 2018. 22(2): p. 119-124.
51. Wegner, I., J.J. Verhagen, I. Stegeman, R. Vincent, and W. Grolman, A systematic review of the effect of piston diameter in stapes surgery for otosclerosis on hearing results. *Laryngoscope*, 2016. 126(1): p. 182-190.
52. Laske, R.D., C. Roosli, M.V. Chatzimichalis, J.H. Sim, and A.M. Huber, The influence of prosthesis diameter in stapes surgery: a meta-analysis and systematic review of the literature. *Otol Neurotol*, 2011. 32(4): p. 520-528.
53. Wegner, I., M.M. Eldaebes, T.G. Landry, W. Grolman, and M.L. Bance, The Effect of Piston Diameter in Stapedotomy for Otosclerosis: A Temporal Bone Model. *Otol Neurotol*, 2016. 37(10): p. 1497-1502.
54. Hausler, R., C. Stieger, H. Bernhard, and M. Kompis, A novel implantable hearing system with direct acoustic cochlear stimulation. *Audiol Neurootol*, 2008. 13(4): p. 247-256.
55. Shimizu, Y., S. Puria, and R.L. Goode, The floating mass transducer on the round window versus attachment to an ossicular replacement prosthesis. *Otol Neurotol*, 2011. 32(1): p. 98-103.
56. Calvino, M., I. Sanchez-Cuadrado, J. Gavilan, and L. Lassaletta, Cochlear Implant Users with Otosclerosis: Are Hearing and Quality of Life Outcomes Worse than in Cochlear Implant Users without Otosclerosis? *Audiol Neurootol*, 2018. 23(6): p. 345-355.
57. Bianconi, L., L. Gazzini, E. Laura, S. De Rossi, A. Conti, and D. Marchioni, Endoscopic stapedotomy: safety and audiological results in 150 patients. *Eur Arch Otorhinolaryngol*, 2020. 277(1): p. 85-92.

58. Li, J. and L. Ding, Effectiveness of Steroid Treatment for Sudden Sensorineural Hearing Loss: A Meta-analysis of Randomized Controlled Trials. *Ann Pharmacother*, 2020. 54(10): p. 949-957.
59. Stachler, R.J., S.S. Chandrasekhar, S.M. Archer, R.M. Rosenfeld, S.R. Schwartz, D.M. Barrs, S.R. Brown, T.D. Fife, P. Ford, T.G. Ganiats, D.B. Hollingsworth, C.A. Lewandowski, J.J. Montano, J.E. Saunders, D.L. Tucci, M. Valente, B.E. Warren, K.L. Yaremchuk, and P.J. Robertson, Clinical practice guideline: sudden hearing loss. *Otolaryngol Head Neck Surg*, 2012. 146(3 Suppl): p. S1-35.
60. Kumagami, H., M. Terakado, and H. Takahashi, Distribution of glucocorticoid receptors and 11 $\beta$ -hydroxysteroid dehydrogenase isoforms in the human inner ear. *Otol Neurotol*, 2013. 34(1): p. 151-157.
61. Maeda, K., K. Yoshida, I. Ichimiya, and M. Suzuki, Dexamethasone inhibits tumor necrosis factor-alpha-induced cytokine secretion from spiral ligament fibrocytes. *Hear Res*, 2005. 202(1-2): p. 154-160.
62. Tahera, Y., I. Meltser, P. Johansson, Z. Bian, P. Stierna, A.C. Hansson, and B. Canlon, NF-kappaB mediated glucocorticoid response in the inner ear after acoustic trauma. *J Neurosci Res*, 2006. 83(6): p. 1066-1076.
63. MacArthur, C., F. Hausman, B. Kempton, and D.R. Trune, Intratympanic Steroid Treatments May Improve Hearing via Ion Homeostasis Alterations and Not Immune Suppression. *Otol Neurotol*, 2015. 36(6): p. 1089-1095.
64. Ç Çelik, M.C., A Aliyeva, U Düzenli, A Dalgıç, The Effect Of Perioperative I.V. Corticosteroids On Hearing Outcome Following Stapedotomy. *ENT UPDATES*, 2018. 8(2): p. 82-87.
65. Riechelmann, H., M. Tholen, T. Keck, and G. Rettinger, Perioperative glucocorticoid treatment does not influence early post-laser stapedotomy hearing thresholds. *Am J Otol*, 2000. 21(6): p. 809-812.

66. Enticott, J.C., H.T. Eastwood, R.J. Briggs, R.C. Dowell, and S.J. O'Leary, Methylprednisolone applied directly to the round window reduces dizziness after cochlear implantation: a randomized clinical trial. *Audiol Neurootol*, 2011. 16(5): p. 289-303.
67. El-Hennawi, D.M., M.H. El-Deen, A.S. Abou-Halawa, H.S. Nadeem, and M.R. Ahmed, Efficacy of intratympanic methylprednisolone acetate in treatment of drill-induced sensorineural hearing loss in guinea pigs. *J Laryngol Otol*, 2005. 119(1): p. 2-7.
68. Kiefer, J., Q. Ye, J. Tillein, O. Adunka, W. Arnold, and W. Gstottner, Protecting the cochlea during stapes surgery: is there a role for corticosteroids? *Adv Otorhinolaryngol*, 2007. 65: p. 300-307.
69. Ye, Q., J. Tillein, R. Hartmann, W. Gstottner, and J. Kiefer, Application of a corticosteroid (Triamcinolon) protects inner ear function after surgical intervention. *Ear Hear*, 2007. 28(3): p. 361-369.
70. Magliulo, G., P. Cristofari, and G. Terranova, Functional hearing results in revision stapes surgery. *Am J Otol*, 1997. 18(4): p. 408-412.
71. Pedersen, C.B., Revision surgery in otosclerosis--an investigation of the factors which influence the hearing result. *Clin Otolaryngol Allied Sci*, 1996. 21(5): p. 385-388.
72. Kanona, H., M.F. Bhutta, and J. Lavy, Our approach to revision stapes surgery and the outcomes from 49 procedures at a UK tertiary centre. *Clin Otolaryngol*, 2017. 42(4): p. 931-935.
73. Mahendran, S., R. Hogg, and J.M. Robinson, To divide or manipulate the chorda tympani in stapedotomy. *Eur Arch Otorhinolaryngol*, 2005. 262(6): p. 482-7.
74. Guinand, N., T. Just, N.W. Stow, H.C. Van, and B.N. Landis, Cutting the chorda tympani: not just a matter of taste. *J Laryngol Otol*, 2010. 124(9): p. 999-1002.

75. Mangham, C.A., Jr., J. Neel, and H.F. Mangham, Success of five stapes prostheses evaluated by Kaplan-Meier product-survival procedure. *Otol Neurotol*, 2008. 29(7): p. 900-904.
76. Andersen, S.A.W., M.C. Ohman, and M.S. Sorensen, The stability of short-term hearing outcome after stapedotomy: a prospective database study. *Acta Oto-Laryngologica*, 2015. 135(9): p. 871-879.
77. Szekely, L., A. Gaborjan, K. Danos, T. Szaloki, Z. Fent, L. Tamas, and G. Polony, Mid-term evaluation of perioperative i.v. corticosteroid treatment efficacy on overall and audiological outcome following CO2 laser stapedotomy: a retrospective study of 84 cases. *Eur Arch Otorhinolaryngol*, 2020. 277(4): p. 1031-1038.
78. Polony G, G.A., Tamás L, Székely L, Revision Stapedotomies: the Role of Periprosthetic Scar Tissue Formation in the Development of Unsatisfactory Hearing Results after Stapedotomy. *INTERNATIONAL ARCHIVES OF OTORHINOLARYNGOLOGY*, 2021(paper in press).
79. Wilson, W.R., F.M. Byl, and N. Laird, The efficacy of steroids in the treatment of idiopathic sudden hearing loss. A double-blind clinical study. *Arch Otolaryngol*, 1980. 106(12): p. 772-776.
80. Holund, B., P. Junker, P. Christoffersen, H. Lyon, and I. Lorenzen, The effect of D-penicillamine and methylprednisolone on the morphology of experimental granulation tissue in rats. *Acta Pathol Microbiol Immunol Scand A*, 1982. 90(1): p. 51-55.
81. Hettrich, C.M., E.F. DiCarlo, D. Faryniarz, K.B. Vadasdi, R. Williams, and J.A. Hannafin, The effect of myofibroblasts and corticosteroid injections in adhesive capsulitis. *J Shoulder Elbow Surg*, 2016. 25(8): p. 1274-1279.
82. Ehrchen, J.M., J. Roth, and K. Barczyk-Kahlert, More Than Suppression: Glucocorticoid Action on Monocytes and Macrophages. *Front Immunol*, 2019. 10: p. 2028.

83. Li, J., C. Heinz, B. Zurek-Imhoff, and A. Heiligenhaus, Intraoperative intraocular triamcinolone injection prophylaxis for post-cataract surgery fibrin formation in uveitis associated with juvenile idiopathic arthritis. *J Cataract Refract Surg*, 2006. 32(9): p. 1535-1539.
84. Shaban, M., Y. Aras, A. Aydoseli, M.O. Akcakaya, A. Sencer, C. Bayindir, and N. Izgi, Effects of sodium hyaluronate and methylprednisolone alone or in combination in preventing epidural fibrosis. *Neurol Res*, 2013. 35(8): p. 851-856.
85. Nakano, M., H. Matsui, K. Miaki, and H. Tsuji, Postlaminectomy adhesion of the cauda equina. Inhibitory effects of anti-inflammatory drugs on cauda equina adhesion in rats. *Spine (Phila Pa 1976)*, 1998. 23(3): p. 298-304.
86. Vander Salm, T.J., O.N. Okike, T.H. Marsicano, C. Compton, and E. Espinoza, Prevention of postoperative pericardial adhesions. An animal study. *Arch Surg*, 1986. 121(4): p. 462-467.
87. Souza, J.C., R.F. Bento, L.V. Pereira, L. Ikari, S.R. Souza, A.A. Della Torre, and A.C. Fonseca, Evaluation of Functional Outcomes after Stapes Surgery in Patients with Clinical Otosclerosis in a Teaching Institution. *Int Arch Otorhinolaryngol*, 2016. 20(1): p. 39-42.
88. Ziylan, F., D.P.J. Smeeing, A. Bezdjian, I. Stegeman, and H. Thomeer, Feasibility of preservation of chorda tympani nerve during noninflammatory ear surgery: A systematic review. *Laryngoscope*, 2018. 128(8): p. 1904-1913.
89. Berling Holm, K., J. Knutsson, K. Stromback, N. Danckwardt Lilliestrom, G. Papatziarnos, A. Rosenblad, and M. Von Unge, Taste disturbance after stapes surgery: an evaluation of frequency, severity, duration, and quality-of-life. *Acta Otolaryngol*, 2017. 137(1): p. 39-43.
90. Choi, N., J. Ahn, and Y.S. Cho, Taste Changes in Patients With Middle Ear Surgery by Intraoperative Manipulation of Chorda Tympani Nerve. *Otol Neurotol*, 2018. 39(5): p. 591-596.



All the illustrations included in the manuscript are the work of the author.

## 8 Bibliography of the candidate's publications

1.

Polony, G ; Gáborján, A; Tamás, L ; **Székely, L**✉

Revision Stapedotomies: the Role of Periprosthetic Scar Tissue Formation in the Development of Unsatisfactory Hearing Results after Stapedotomy

INTERNATIONAL ARCHIVES OF OTORHINOLARYNGOLOGY

26 : 3 pp. e422-e427. 6 p. (2022) 2.

**Székely, L** ✉ ; Gáborján, A ; Dános, K ; Szalóki, T ; Fent, Z ; Tamás, L ; Polony, G

Mid-term evaluation of perioperative i.v. corticosteroid treatment efficacy on overall and audiological outcome following CO(2) laser stapedotomy: a retrospective study of 84 cases

EUROPEAN ARCHIVES OF OTO-RHINO-LARYNGOLOGY 277 : 4 pp. 1031-1038. , 8 p. (2020)

3.

**Székely László**✉; Gáborján Anita; Tamás László; Polony Gábor

Korai posztoperatív ízérzészavar középfülsebészeti beavatkozásokat követően

ORVOSI HETILAP 163 : 23 pp 920-925 (2022)

## 9 Acknowledgements.

I would like to thank my supervisor Polony Gábor for the opportunity to participate in his scientific work, and for his continuous help and guidance during the project. During this time I received the support and motivation which were essential to complete this work.

I am also grateful to Tamás László for the opportunity to work at our department and to attend the PhD program.

Special thanks to my colleagues at the department, for all their help and assistance during everyday practice, and for Dános Kornél and Szalóki Tibor for their help in the PhD project.

I am grateful to my family for their endless support.