


# **Minimally invasive methods in paediatric thoracic surgery**

**Short thesis**

**Dr. Attila György Kálmán**

Semmelweis University  
Doctoral School in Clinical Science for Medicine



**supervisor: Prof. Tivadar Tulassay MD, DSc**

Opponents: Dr. László Harsányi MD, Ph.D.  
Dr. Attila Vástyán MD, Ph.D.

Chairman of the Final Examination Committee: Prof. Katalin Darvas MD, Ph.D.

Members of the Final Examination Committee: Dr. Balázs Hauser MD, Ph.D.  
Dr. Zsolt Juhász MD, Ph.D.

**Budapest**

**2010**

## 1. Introduction

### 1.1. Intrathoracic procedures

Development of anaesthesiology was the first key step in the development of thoracic surgery. Beside proper pain management it made ventilation and gas exchange possible after opening the chest. Pneumonectomy, anatomical lobectomies and segmentectomies were evolved at the beginning of the XX. century.

**Postero-lateral thoracotomy became the standard method** for thoracic procedures.

As mortality and morbidity became lower following major thoracic surgical procedures in the course of time, the cost of the results was taken into consideration.

Trauma of the thoracic wall caused by the thoracotomy is also responsible for pain following thoracic surgery, which is an important factor of postoperative pulmonary complications. Postero-lateral thoracotomy may have consequences affecting the skeletal-muscle system, like scoliosis, asymmetry of the shoulders and winged scapula. Great scar is an obvious disadvantage of standard thoracotomy.

Different muscle-sparing thoracotomies were developed for preventing these short- and long-term complications.

**Axillary skin crease incision** was used by Atkins for sympathectomy. Bianchi published his experience with axillary skin crease incision in neonates in 1998.

Spreading of **thoracoscopic techniques** in thoracic surgery was an other main step from the early nineties. Nearly all thoracic surgeries have been performed thoracoscopically recently.

**Both muscle-sparing thoracotomies and thoracoscopy were waiting for introduction in paediatric surgery in Hungary before the millenary.**

## **1.2. Chest wall deformities**

**Ravitch** published his **thoracoplasty for pectus excavatum** in 1947. He mobilized the sternum radically through a wide exploration of the anterior thoracic wall. Later a metal plate was used as an inner fixation for prevention of recurrence. This method gained worldwide acceptance in the second half of the XX. century.

Long-term follow-up of children operated for chest wall deformities revealed that the chest wall became rigid leading to poor compliance and declining pulmonary function tests. Acquired chondrodystrophy could develop as the worst complication of thoracoplasty. Obvious, sometimes hypertrophic scar is a major disadvantage of traditional thoracoplasties.

**Donald Nuss** published **Minimally Invasive Repair of Pectus Excavatum (MIRPE)**, eliminating most of the disadvantages of traditional thoracoplasties, in 1998. He has elevated the sternum introducing a properly bent metal bar without exploration of the anterior thoracic wall and without the transection of the ribs or the sternum. The bar kept the sternum in place during the period of remodelling of the chest wall, which occurred in 2-3 years. This operation means much less load for the patient than the traditional open thoracoplasty. It doesn't leave scar on the anterior thoracic wall, and the elasticity and compliance of the chest wall are maintained.

MIRPE displaced Ravitch procedure worldwide and difficulties of it delineated gradually. Displacement of the bar is the commonest complication

occurring in 10 % in most published series. The procedure is not ideal for markedly asymmetric deformities. Open thoracoplasty is still used in these cases.

András Hock has invented minimally invasive operation for **pectus carinatum** using the principle of Donald Nuss. He corrected the deformity with a bar stressing the sternum backwards and ending in the thoracic cavity on both sides. He reported excellent results, but he experienced major difficulties during removal of the bar. Similar procedure was published by Abramson in 2005, but his bar was outside the chest wall in its whole length, and the bar was fixed to the ribs with wires at both ends.

## 2. Objectives

Our aim was to introduce different minimally invasive techniques in paediatric thoracic surgery in Hungary. Our aim was to assess our results continuously, to improve these procedures and to spread them in Hungary.

### 2.1. Intrathoracic procedures

We were intent on using minimally invasive techniques meaning less load and leaving less scar instead of the postero-lateral thoracotomy used previously in Hungary:

**2.1.1. axillary skin crease incision** for procedures in the upper part of the thoracic cavity

**2.1.2. thoracoscopy** for benign diseases

### 2.2. Chest wall deformities

We introduced minimally invasive techniques instead of the Ravitch procedure in Hungary:

**2.2.1.** We used MIRPE of Nuss for correcting **pectus excavatum** and we improved it in many parts.

**2.2.2.** We used minimally invasive repair of **pectus carinatum**, which was published by me.

### 3. Patients and methods

#### 3.1. Intrathoracic procedures

We performed 571 intrathoracic operations in the period 1999-2009, 242 (42 %) axillary skin crease incisions, 169 (30 %) thorascopies and 160 (28 %) postero-lateral thoracotomies.

##### 3.1.1. Axillary skin crease incision

We used axillary skin crease incision from neonates to adolescents, when we performed operation in the upper part of the chest.

We performed the skin incision in one of the skin creases running in the armpit. M. latissimus dorsi and m. pectoralis maior were left intact and the fibers of m. serratus anterior were splitted. Thoracotomy was done in the 3<sup>rd</sup> of 4<sup>th</sup> intercostal space.

Postero-lateral thoracotomy was used for operations in the lower part of the chest, when we removed a huge tumour and in extremely small prematures (<700-800 g).

#### **The 242 proecdures done through axillary skin crease incision:**

Oesophageal atresia	86
Tracheo-oesophageal fistula (TOF)	3
Patent ductus arteriosus	119
Congenital lung malformation	7
Destroyed lobe of the lung	6

Atypical lung resection	5
Neurogenic tumour	7
Anterior mediastinal tumour	5
Bronchogenic cyst, thymic cyst, rib resection, aortopexy	1-1

There were 81 **oesophageal atresia** with distal tracheo-oesophageal fistula, 4 pure oesophageal atresia and 1 oesophageal stenosis.

We ligated the patent ductus arteriosus of low birth weight prematures, who had Botallo duct with clinically significant left-right shunt and it didn't close despite conservative treatment.

### 3.1.2. Thoracoscopy

We performed thoracoscopy from neonates to young adults for benign diseases and for smaller neurogenic tumours arising from the posterior mediastinum.

We performed **169 thoracoscopies** in our department:

Sympathectomy	66 + 1
Empyema thoracis	32
Lung and mediastinal biopsy, atypical resection	17
Cysta bronchogenes seu pericardii	11
Neurogenic tumour	10
Pneumothorax	7
Hernia seu eventeration of the diaphragm	6
CCAM, sequestration	4
Echinococcus cyst	3
Oesophageal duplication	2

Closure of TOF	2
Foreign body (drain, airgun bullet)	2
Else	6

We performed **sympthectomy** for refractory long QT (LQT) syndrome in one case and for essential hyperhidrosis in 66 cases.

We removed Th. 2-3-4. ganglia on both sides in our first 20 patients with hyperhidrosis. From the 21. patient we blocked Th. 2-3. ganglia with titanium clips for lessening the symptoms of compensatory sweating and to provide reversibility of the procedure.

We performed thacoscopy in our febrile patients with **parapneumonic empyema**, if ultrasound showed large, thick, septated fluid collection in the thoracic cavity.

We opened the pleural space and cleared both the visceral and the parietal pleura from fibrinous material. We left drains in the chest, and performed fibrinolysis in the postoperative period when it was necessary.

### **3.2. Chest wall deformities**

**All our patients with chest wall deformity were operated with minimally invasive technique in the 2000-2009 period.** Our patients were prospectively followed-up.

#### **3.2.1. Pectus excavatum**

**MIRPE invented by Nuss was used in 414 patients with pectus excavatum.** (Fig. 1.) Our patients were  $14,5 \pm 3,5$  years old, male : female ratio



was 3,5 : 1. There were 6 patients with Marfan syndrome. 11 patients had traditional open thoracoplasty done previously.

We used the stainless steel T-bar invented with Sanatmetal Ltd. The bar is 15 mm wide and 2 or 3 mm thick depending on the length of the bar. The proper sized bar was bent before the operation.

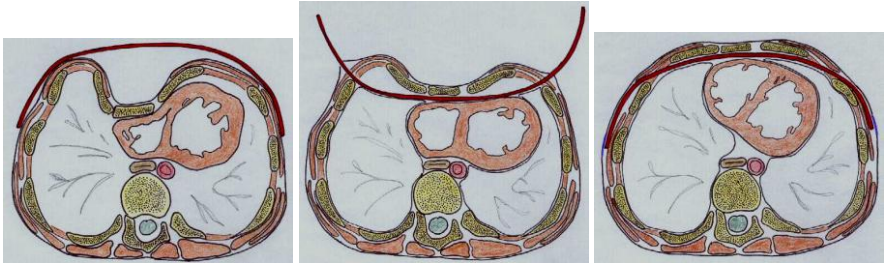


Fig. 1.a-c Main steps of MIRPE

The follow-up was 4 years long (1 month – 9,5 years). We reviewed and assessed the events of the perioperative and postoperative period. We asked 99 patients and their parents to evaluate the aesthetic and functional results of the operation on a 1-5 scale.

### 3.2.2. Pectus carinatum

We operated **30 patients with pectus carinatum in the 2005-2009 period** using my invention of minimally invasive technique based on the method of András Hock. (Fig. 2)

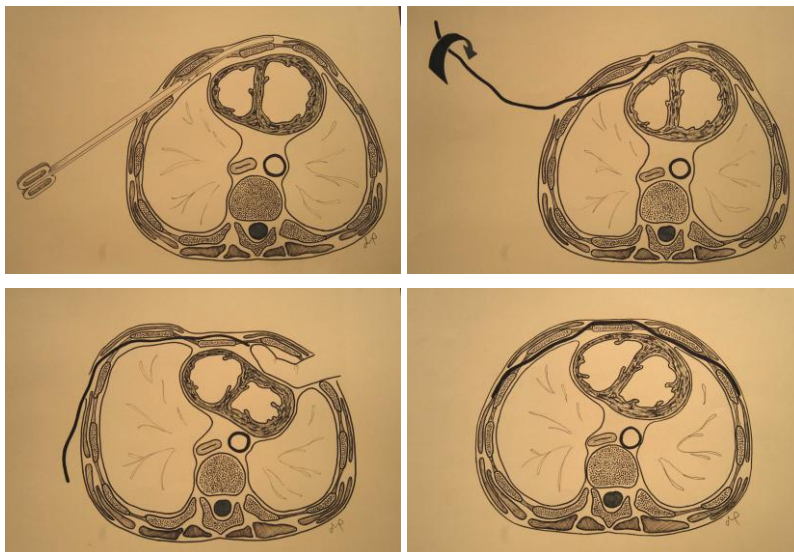


Fig.2.a-d Our minimally invasive procedure for pectus carinatum repair

Our patients were  $14,5 \pm 3$  years, there were 4 girls and 26 boys. 12 patients had markedly asymmetric deformity with rotation of the sternum.

We used the bar developed for the minimally invasive correction of pectus excavatum.

The follow-up was 21 months long (3 months – 4,5 years). We reviewed and assessed the events of the perioperative and postoperative period. Our first 14 patients evaluated the postoperative appearance of the chest on a 1-5 scale (excellent, very good, good, fair, poor).

## 4. Results

### 4.1. Intrathoracic procedures

#### 4.1.1. Axillary skin crease incision

Thoracotomy in the 4<sup>th</sup> intercostal space performed through axillary skin crease incision provided good exposure for all the 81 patients with oesophageal atresia with distal tracheo-oesophageal fistula (OA+TOF).

We had no intraoperative complication. There was one (1,2 %) anastomosis leakage in the postoperative period. He is waiting for substitution of the oesophagus. There were two (2,5 %) disturbed wound-healing in patients with 21 trisomy and congenital heart defect.

We compared the results of our first 7 patients with OA+TOF done through axillary skin crease incision (group I.) with our last 7 patients with OA+TOF done through postero-lateral thoracotomy (group II.). There were no difference between the two groups regarding their gestational age ( $37 \pm 3,2$  wks vs.  $39,6 \pm 1,6$  wks,  $p=0,079$ ), birth weight ( $2304 \pm 553$  g vs.  $2568 \pm 640$  g,  $p=0,212$ ) and the time of operation ( $28,3 \pm 10$  hrs vs.  $31,3 \pm 29$  hrs,  $p=0,800$ ). The duration of the operation was similar ( $104,3 \pm 26$  mins vs.  $90,7 \pm 11,3$  mins,  $p=0,115$ ). The duration of postoperative ventilation need was the same ( $5 \pm 1,15$  days vs.  $5,3 \pm 1,7$  days,  $p=0,36$ ). There was neither anastomosis leakage nor wound healing problem in any groups. Two patients needed dilatation in the axillary group and one in the postero-lateral group. One patient with severe gastro-oesophageal reflux needed fundoplication in the I. group.

Ligation of **patent ductus arteriosus** was successful in every case. We experienced bleeding from the duct in 2 patients (1,7 %). We could manage the bleedings with suture ligation of the duct.

Our **oldest patient was 15** years old, in whom we performed axillary skin crease incision. We removed a teratoma arising from her anterior mediastinum.

#### **4.1.2. Thoracoscopy**

159 of the 169 thoracoscopies were finished thoroscopically. We had to convert the operation to open thoracotomy in 10 cases (6 %)

The youngest sympathectomized patient published in the literature was 6 years old. We performed an **uneventful thoroscopic left Th. 1-4. sympathectomy with removal of the stellate ganglion in an 8 months old infant with refractory long QT syndrome.**

We performed **thoroscopic sympathectomy** in adolescents and young adults **for essential hyperhidrosis** in 66 cases.

63 patients were emitted on the 1. postoperative day. No case of Horner's triad was observed in our patients as a late complication.

Increased palmary sweating was ceased in all cases (59 patients), while increased axillary sweating was ceased in 59 of 61 patients.

Infiltrated lung was injured during two thoracoscopies for **empyema**. The small leakage of air was drained in these cases and no surgical intervention became necessary.

## 4.2. Chest wall deformities

### 4.2.1. Pectus excavatum

I performed the first MIRPE in Hungary on 17<sup>th</sup> May, 2000. We modified the original procedure of Donald Nuss in several details later.

**1. I have developed a T-bar for the procedure in collaboration with the Sanatmetal Ltd.** It's made in 200 – 440 mm range, it's 15 mm wide, the shorter ones ( $\leq 300$  mm) are 2 mm thick, the longer ones ( $\geq 320$  mm) are 3 mm thick. One end of the bar has T-shape.

**2. We used bilateral thoracoscopy** for increasing safety.

**3. We introduced the instrument from left in every case** to prevent injury of the heart.

**4. In cases of severe deformities we lifted the sternum with a bone-hook** inserted next to the xyphoid process.

**5. We bent the middle part of the bar in saddle-shape** from the 7<sup>th</sup> patient following the suggestion of András Farkas. It increased the stability of the bar and lessened the chance of overcorrection of the deformity.

**6. The sternum has a sharp angle caudal to the manubrium** in some cases of pectus excavatum. **We made a transverse sternotomy** at the sternal angle through a 2,5 – 3 cm incision **for the correction of these deformities in 7 cases.**

**7. The sternum is rotated (usually to the right)** in cases of **asymmetric pectus excavatum.** We used an **asymmetric bar placed below the depressed costal arch** to correct these deformities in 9 cases.

One bar was enough in 369 patients, 43 patients needed 2 bars. We placed 3 bars in two tall, asthenic patients with severe asymmetric deformity.

No transfusion was needed intra- or postoperatively. The duration of the procedure was  $43 \pm 21$  minutes. The patients were emitted on the 5. postoperative day (median, quartiles: 4-5).

Three patients (0,7 %) had pneumothorax necessitating tube insertion during the stay in hospital. Three patients (0,7 %) experienced early bar displacement.

Three patients (0,7 %) had haemothorax and two patients (0,5 %) had hydrothorax necessitating drainage in the late postoperative period. They didn't need transfusion. Three patients (0,7 %) experienced late bar displacement (2, 5 and 12 months following the procedure).

There were 5 bar displacement among our first 76 patients (6,6 %). There was only 1 bar displacement among our last 338 patients having their bar bent in saddle-shape (0,3 %).

We removed the bar from 273 patients  $29 \pm 6$  months following its insertion. There was one bleeding from the area of the mammary arteries during bar removal. 3 patients (1,1 %) experienced recurrence of deformity during the 37 months (1 month – 7 years) after removal of the bar. Two of them had uneventful repeated MIRPE.

Our first 99 patients and their parents assessed the aesthetic result of the procedure  $4,6 \pm 0,66$ . The functional result was assessed  $4,8 \pm 0,52$ .

#### **4.2.2. Pectus carinatum**

Two bars were inserted in one of our patients with very asymmetric deformities. One bar was enough in all other cases, even in asymmetric cases. There was no transfusion required. The duration of the operation was  $39 \pm 17$  minutes. The patients were emitted on the 4. day (median, quartiles: 3-4).

There was no complication during the operation or the early postoperative period.

The bar was slipped laterally on the 7. postoperative week in our oldest (18,5 years) patient. The bar was bent again and its position was corrected.

13 of our first 14 patients reported excellent or very good result, and one patient reported good result.

All our patients regained full activity within 2 months.

We removed the bar from our first 10 patients  $26 \pm 3$  months following correction of deformity. All our patients were discharged on the day following the operation. The shape of the chest of the patients didn't change during the 6 months – 2,5 years following bar removal.

## 5. Conclusions

**5.1. Axillary skin crease incision** can be used in more indications and in wider age group than it is originally published by Bianchi.

- There's no difference between axillary skin crease incision and postero-lateral thoracotomy regarding the results of repair of oesophageal atresia.
- Axillary skin crease incision provides proper exposure for ligation of patent ductus arteriosus except the extremely low birth-weight prematures.

**5.2. Thoracoscopy** is safe in childhood with low conversion rates.

- Thoracoscopic sympathectomy can be performed safely in cases of long QT syndrome refractory to conservative treatment in infants too.
- Blocking of ganglia with clips has the same effect as excision of ganglia has in the treatment of hyperhidrosis. Horner's triad can be prevented. Sympathectomy can be done on both sides simultaneously, it doesn't increase the risk of the procedure.

**5.3. MIRPE** is effective for correction of **pectus excavatum**.

- The T-bar developed in collaboration with Sanatmetal Ltd. can be used during the procedure.
- Safety of the method can be increased, risk of major complications can be minimized with our modifications of the procedure (use of thoracoscopy, insertion of the instrument from left, elevation of the sternum).
- Bar displacement can be prevented with saddle-shape bending of the bar.
- Asymmetric deformities can be corrected with other modifications of the procedure (insertion of 2 or 3 bars, insertion of a bar below the costal arch).
- Deformities with sharp angle can be corrected with addition of sternotomy to the procedure.



**5.4. Pectus carinatum** can be corrected with the minimally invasive procedure invented by us. This is true for symmetric and asymmetric cases too.

## **Publications of the author related to the thesis**

### **Articles:**

1. Andrew Pintér, **Attila Kálmán**, Levente Karsza, Tibor Verebély, Ferenc Szemlédy: Long-term outcome of congenital cystic adenomatoid malformation. *Pediatric Surgery International*, 1999; 15: 332-335 **IF: 0,500**
2. **Attila Kálmán**, Tibor Verebély: The use of axillary skin crease incision for thoracotomies of neonates and children. *European Journal of Pediatric Surgery*, 2002; 12: 226-229 **IF: 0,425**
3. **Kálmán Attila**, Verebély Tibor: A pectus excavatum műtéti megoldása minimálisan invazív módszerrel. *Granum*, 2004; 7: 32-34
4. **Kálmán Attila**: Minimálisan invazív módszerek a gyermek mellkasebészetben. *Gyermekorvos továbbképzés*, 2005; 4: 124-128
5. Sárközy Sándor, **Kálmán Attila**: Az Egészségügyi Minisztérium szakmai protokollja a gyermekkori mellúri empyema kezeléséről. *Egészségügyi Közlöny* 2008; 58: 1005-1011
6. **Attila Kálmán**: Initial results with minimally invasive repair of pectus carinatum. *Journal of thoracic and cardiovascular surgery*, 2009; 138: 434-438 **IF: 3,063**

### **Chapter:**

1. Verebély Tibor, **Kálmán Attila**: Mellkasebészeti beavatkozások a gyermekkorban. In: Vadász Pál (szerk.): *Az általános mellkasebészet tankönyve*. Semmelweis Kiadó, Budapest, 2006: 177-192

## **Publications of the author unrelated to the thesis**

- 1. Attila Kálmán**, Zsuzsanna Kálmán, György Velösy, Gábor Vargha, Miklós Papp: Activity of „nonspecific pancreatic carboxylesterase” in rat serum in experimentally induced acute pancreatitis (preliminary results). *Acta Physiologica Hungarica*, 1989; 73: 315-317 **IF: 0,236**
- 2. Tarján Zsolt**, Makó Ernő, Winternitz Tamás, Kiss Imre, **Kálmán Attila**: Az akut appendicitis ultrahangos diagnózisának értékelése. *Orvosi Hetilap*, 1995; 136: 713-717
- 3. Kálmán Attila**, Verebély Tibor, Szabó András, Illyés György: Újszülöttkori primer hyperparathyreosis sikeres műtéti megoldása kisedekorban. *Orvosi Hetilap*, 1996; 137: 1143-1147
- 4. András Treszl**, Erika Héninger, **Attila Kálmán**, Agnes Schuler, Tivadar Tulassay, Barna Vásárhelyi: Lower prevalence of IL-4 receptor  $\alpha$ -chain gene <sup>1902</sup>G variant in very-low-birth-weight infants with necrotizing enterocolitis. *Journal of Pediatric Surgery*, 2003; 38: 1374-1378 **IF: 1,449**
- 5. Kálmán Attila**, Verebély Tibor: Hirschsprung-betegség definitív primer műtéti megoldása kizárólag transanalis úton (transanalis Soave-műtét). *Gyermekgyógyászat*, 2003; 54: 331-335
- 6. Kálmán Attila**: Minimálisan invazív módszerek a gyermekurologiában. *Gyermekorvos továbbképzés*, 2005; 4: 129-131
- 7. Piotr Czuderna**, Peter Vajda, Klaus Schaarschmidt, **Attila Kálmán**, Michel Jainsch, A. Engelis, K. Lewicki, Tibor Verebély, J. Koltai, Aigars Petersons, Andrew B. Pintér: Nonparasitic splenic cysts in children: A multicentric study. *European Journal of Pediatric Surgery* 2006; 16: 415-419 **IF: 0,579**
- 8. Illyes, Gyorgy**; Luczay, Andrea; Benyo, Gabor; **Kálmán, Attila**; Borka, Katalin; Koves, Katalin; Racz, Karoly; Tulassay, Tivadar; Schaff, Zsuzsa: Cushing's syndrome in a child with pancreatic acinar cell carcinoma. *Endocrine Pathology*. 2007; 18(2): 95-102 **IF: 1,837**

**9.** Búdi Tamás, **Kálmán Attila**, Györfy Ágnes, Székely Eszter, Verebély Tibor:  
Egy ritka betegség még ritkább lokalizációja: két éves gyermek nyelvcsövéből  
kiinduló juvenilis fibrosarcoma. *Gyermekgyógyászat*. 2009; 60(4): 158-161.