SEMMELWEIS EGYETEM

DOKTORI ISKOLA

Ph.D. értekezések

2447.

BÁNVÖLGYI ANDRÁS

Bőrgyógyászat és venerológia

című program

Témavezető: Dr. Wikonkál Norbert, egyetemi tanár

Programvezető: Dr. Sárdy Miklós, egyetemi tanár

INVESTIGATION OF EFFICACY AND TOLERABILITY OF INNOVATIVE NON-SURGICAL TREATMENTS FOR BASAL CELL CARCINOMA

PhD thesis

András Bánvölgyi

Clinical Medicine Doctoral School

Semmelweis University

Supervisor: Norbert Wikonkál, MD, D.Sc

Official reviewers: György Szabó, MD, D.Sc
Barnabás Horváth, MD, Ph.D

Head of the Complex Examination Committee: Miklós Csala, MD, D.Sc

Members of the Complex Examination Committee: Eszter Baltás, MD,Ph.D
Barbara, Molnár-Érsek, MSc, Ph.D

Budapest
2020

Table of Contents

List of Abbreviations

AEs Adverse events
AF atrial fibrillation
BCC Basal cell carcinoma
C. albicans Candida albicans
CR Complete response
CT Computer tomography
EMA European Medicines Agency
ETC Electron transport chain
FDA Food and Drug Administration
GLI Glioma associated oncogene
H_2O_2 Hydrogen peroxide
HE hematoxylin and eosin
Hh Hedgehog protein
$HO^{\cdot}$ Hydroxyl radical
HT Hypertension
ICD International Statistical Classification of Diseases
IVA Intravenous ascorbic acid
laBCC Locally advanced BCC
mBCC Metastatic BCCs
MMS Mohs micrographic surgery
MRI Magnetic resonance imaging
NBCCS Nevoid basal cell carcinoma syndrome
NIDDM Non-insulin dependent diabetes mellitus
ORR Objective response rate
PBS Phosphate buffered saline
PD Progressive disease
PR Partial response
Ptc Patched protein
PTCH Patched gene
PTCH1 Patched 1 gene
QOL Quality of life
RECIST Response Evaluation Criteria in Solid Tumors
ROS Reactive oxygen species
SD Stable disease
SD Standard deviations
SHh Sonic hedgehog
Smo Smoothened protein
SMO Smoothened gene
SUFU Suppresses of Fused gene
YPD Yeast extract peptone dextrose

1. Introduction

1.1 Basal cell carcinoma

1.1.1 Epidemiology

Basal cell carcinoma (BCC) is the most common malignancy in the fair-skinned population, however associated mortality is very low and metastasis is an extreme rarity (1, 2). It has a lifetime prevalence of 20–30% (1)and the likelihood of developing BCC is higher at older ages. Sunburn damage during childhood and intermittent UV radiation altogether play a primary role in its development (1, 3). The incidence of BCC, and with it the cost burden on the health care system is increasing (3). Presumably BCCs are often not adequately registered in national cancer registries, due to the lack of specific International Statistical Classification of Diseases (ICD) code, hence their incidence is most likely underestimated (3).

1.1.2 Genetic background

Genetic mutations in a hereditary syndrome, nevoid basal cell carcinoma syndrome (NBCCS), also known as Gorlin-Goltz syndrome, predispose to the formation of BCCs (4-7). In NBCCS Patched 1 (*PTCH1*) gene alterations are the most common, but changes in Smoothened (*SMO*) and the Suppressor of Fused (*SUFU*) genes have also been identified. These mutations lead to the development of classic Gorlin-Goltz syndrome, with multiple BCCs, that emphasises the role of sonic hedgehog (SHh) pathway related changes in the genetic background of BCCs (6, 8, 9). The Patched protein (Ptc), encoded by the *PTCH1* gene, is a transmembrane receptor of the hedgehod (Hh) ligands with a tumor suppressor effect. It acts as a repressor of Smoothened (Smo) protein, which is a 7-pass transmembrane receptor. *SMO* has been shown to have a role as an oncogene in the development of basal cell carcinoma, medulloblastoma, and prostate cancer (10, 11). As a result of the presence of Hh, Smo is released from the repression of Ptc, and – as a consequence - the signal transduction pathway becomes activated. In NBCCS the result of the loss-of-function mutation in *PTCH1* can interfere with the inhibition of Smo, which leads to an upregulated and constant activation of transcription of target oncogenes (6, 7, 12). In other reported cases the gain of function mutations in *SMO* gene leads to the

unregulated activation of the Hh pathway (9, 13, 14). In NBCCS due to the constant activation of the Hh pathway multiple or extensive locally advanced BCCs develop.

1.1.3 Traditional therapies for basal cell carcinoma

Surgical excision is the gold standard method to treat BCCs with a high curative rate of approximately 95% (15, 16). It also gives a favourable cosmetic outcome in the vast majority of patients. In a number of cases, as in locally advanced BCCs (laBCC) and certain subtypes, other treatment modalities are preferred. For large tumors and those which show aggressive histological features Mohs micrographic surgery (MMS) is the gold standard (15). Radiotherapy can be an alternative choice for patients when surgery is contraindicated, though it is now being chosen less commonly (15, 16). It is known that radiotherapy can promote tumor formation thus in NBCCS it is not recommended (17). In cases of low-risk lesions techniques as cryosurgery, photodynamic therapy, ablative laser, curettage or imiquimod cream are also applicable (15, 16, 18).

1.1.4 Non-surgical modern systemic therapy for basal cell carcinoma

Most BCC's are relatively harmless, yet there are extensive forms of laBCCs and cases of metastatic BCCs (mBCC) that are incurable with surgery or radiotherapy, or only through severe aesthetic and / or functional loss. The US Food and Drug Administration (FDA) approved the Smoothened (Smo) inhibitor drug vismodegib (Erivedge, Genentech / Roche) in 2012, as a novel treatment option for the treatment of cases which are incurable with surgery or radiotherapy (19). The European Medicines Agency (EMA) followed FDA in 2013 (19). The mechanism of action and the Hh pathway itself is described in Fig. 1.

Sonidegib (Odomzo, Novartis), as another Smo inhibitor got the permission by the FDA and EMA in 2015 (20). Nowadays Smo inhibitor vismodegib is considered to be the first-line treatment (21, 22) for selected cases. These are tumors that are irresectable, or the removal would cause severe aesthetic deformity and loss of function. Additionally, vismodegib can be the optimal choice of treatment in NBCCS when large number of lesions would require extensive and repeated operations (21). In the ERIVANCE study

vismodegib showed remarkable response rates for laBCCs. The objective response rate (ORR) was 60.3%, including 31.5% complete response (CR) and a significant 28.4% partial response (PR) rate (21).

Despite the impressive efficacy of vismodegib one cannot underestimate the high rate of the severe drug-related adverse events (AEs)(21). Vismodegib can cause side-effects as muscle spasms, fatigue, universal alopecia, dysgeusia, loss of appetite and weight loss.

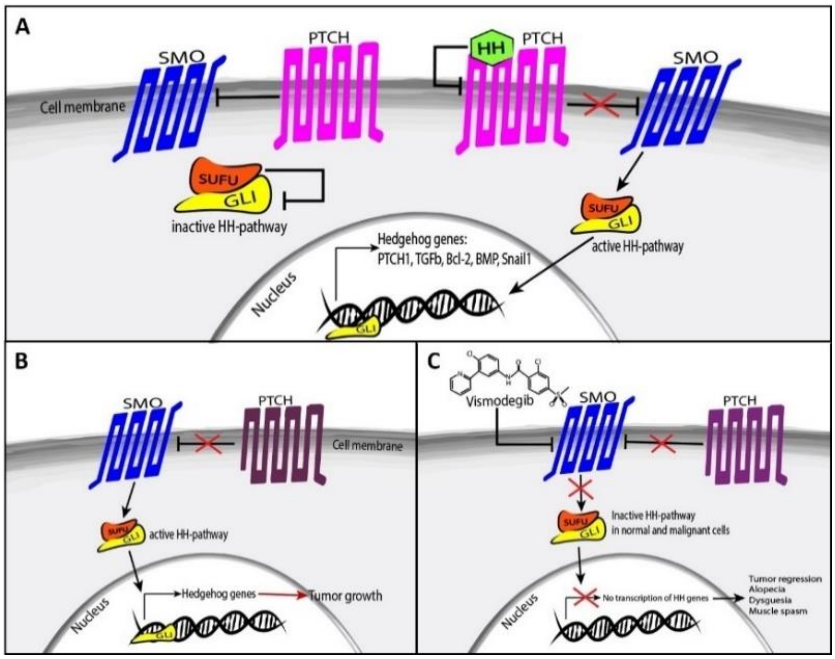

Figure 1. The representation of the mechanism of action of vismodegib together with the Hh pathway. In case of normal function, without Hh ligand Smo is suppressed by PTCH. Smo can be released from inhibition with the binding of Hh ligand to PTCH. HH pathway is inactive in most organs during adulthood, it still has a remarkable role in the maintenance of selective tissues (14). (A) In NBCCS, the mutation of Ptc leads to the inability to inhibit Smo, consequently upregulate Hh genes and further cause the formation of multiple BCCs (6). (B) Vismodegib is a Smo-inhibitor agent that binds to Smo, suppress its function and subsequently inhibit tumorigenesis of BCC. This effect is also responsible for the development of side effects (14).

To date, the exact pathomechanism that explains muscle cramps is not understood. The skeletal muscle cell differentiation, proliferation and survival are affected by the Hh pathway (23). Nevertheless, according to other reports, vismodegib presumably activates the cell membrane calcium channels, which leads to muscle spasms (24). Conversely, it is well established that the role of the Hh pathway in hair follicles and the taste papilla

results in AEs such as alopecia and dysgeusia, respectively (25). When the regular function of Hh pathway in follicular growth regulation and the switch from telogen to anagen phase is hampered, this consequently leads to alopecia. Consistent with this phenomenon, it was presumed that a Hh pathway agonist can induce hair growth in mice (26). Regarding dysgeusia the inhibition of glioma associated oncogene (GLI) transcriptional activity, caused by the disruption of the Hh signalling, leads to taste dysfunction. The GLI activity is crucial for continuous replacement of the taste papilla and taste bud cells, which is a necessity for the adequate tasting function (27). As the innervation of the tasting cells remains intact, after the discontinuation of the vismodegib, the tasting function regains its original activity (25). It must be emphasized that Smo-inhibitors, among vismodegib, are embryo- and fetotoxic with teratogenic effects due to the inhibition of the Hh pathway. Therefore, it is strictly forbidden to administer vismodegib during pregnancy. Though BCCs develop mostly in older age, in cases of female NBCCS patients it could be a significant issue (25, 28).

These drug-related AEs could severely impair the quality of life (QOL) and may result in the discontinuation of the therapy in a significant proportion of patients (2, 21). In the ERIVANCE trial, a remarkably high percentage, 17% of patients decided to discontinue the Smo-inhibitor therapy due to AEs (19). As the suspension of a drug could lead to the development of secondary resistance it is vital in oncology to avoid discontinuation of a treatment due to AEs. In addition, both primary and secondary drug-resistance to vismodegib have been reported and these were explained multiple pathways. Mutations of the Smo or the upregulation of the downstream signalling or other selective pathways, as e.g. PI3 kinase, can all contribute to the loss of the therapeutic effect (29-31).

Switching to sonidegib, as the other FDA approved Smo-inhibitor, usually does not provide a solution in such cases of secondary resistance. Nowadays, off-label use of PD1 inhibitors are increasingly popular as alternatives for Smo-inhibitor resistant laBCCs (32). However, we must emphasize that frequently anti-PD1 drugs cannot be chosen due to comorbidities. Resistance to anti-PD1 drugs may also develop in certain BCCs. Also, as anti PD-1 therapies have a substantial cost, their use may be limited for financial reasons. For such patients there is a need to find further therapeutic options, either alone or as an adjuvant therapy with minimal side-effects.

1.2 Ascorbic acid

Ascorbic acid (ascorbate, vitamin C), first isolated and discovered by the Hungarian Nobel-prize laureate Albert Szent-Györgyi, is an essential vitamin most well-known for its potent antioxidant properties (33).

1.2.1 Pro-oxidant effects of ascorbic acid

In addition to its antioxidant effects, studies have also shown that high-dose ascorbate have a cytotoxic effect on cancer cells (33). It has been postulated that for this pro-oxidant property, ascorbate can exert antitumor effects *in vivo*. In high intra- and extracellular concentration it can achieve the reduction of metal ions, such as copper or iron (34, 35). This subsequently leads to the generation of superoxide, hydrogen peroxide (H_2O_2) and hydroxyl radical ($HO^{\cdot}$) during the Fenton reaction, although the exact cytotoxic mechanism is still not well understood. The basis of the process is the Fenton reaction, where ferric iron (Fe^{3+}) is produced, and then ferric iron can be reduced back to Fe^{2+} (Fig.2) (34).

The potential use of ascorbate as an active ingredient, is not just limited to the field of oncology, but it can also be considered a drug of use for treating infectious diseases as several studies revealed its anti-infective abilities (36-38). Brajtburg et al. showed that ascorbate, as an adjuvant therapy, boosted the cytotoxic effects of amphotericin B on *Cryptococcus neoformans* and *Candida albicans* (*C. albicans*) cells (38). A separate study demonstrated in an in vivo mouse model that a combination of low-dose amphotericin B and high concentrations of ascorbate was effective against recurrent candidemia sepsis (39).

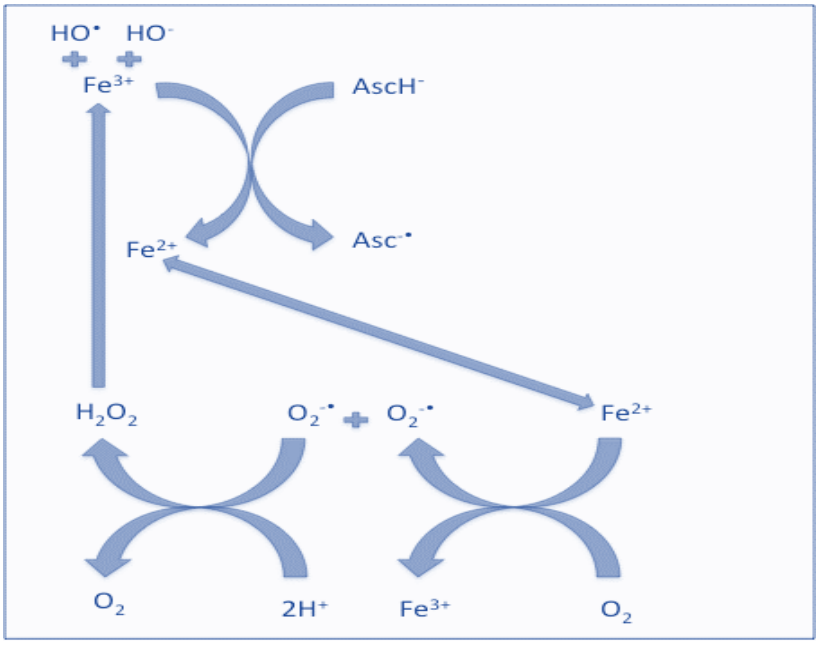

Figure 2. Ferric iron (Fe^{3+}) can be reduced by ascorbate monoanion ($AscH^-$), which is a one-electron reducing agent, to ferrous (Fe^{2+}) iron. This also produce ascorbate radical ($Asc^{-\cdot}$). The ferrous (Fe^{2+}) iron formed via this way, added to the present free Fe^2 reacts with O_2 reducing it to superoxide radical ($O_2^{-\cdot}$). It further results in the formation of ferric iron (Fe^{3+}). Afterward O_2^-undergoes dismutation that generate H_2O_2 and O_2. The H_2O_2 formed via this reaction reacts with the Fe^{2+}. In the Fenton reaction it further generates Fe^{3+} and hydroxyl radical ($HO^{\cdot}$). In the presence of ascorbic acid the recycling mechanism of Fe^{3+} back to Fe^{2+} is possible, which in turn let the cycle to continue (40) (with permission)

1.2.2 High-dose intravenous ascorbic acid therapy

In the last decades a growing body of evidence, based mainly on case series, has become available of the possible beneficial use of high dose intravenous ascorbic acid (IVA), however the exact level of the therapeutic effect is still ambiguous (41). According to those case series the IVA treatment can give a favourable therapeutic effect in a variety of malignancies, such as pancreas, prostate, colon and ovarian cancers (42-44). At our department, Holló and colleagues previously published a study, that showed therapeutic effect of topically applied ascorbic acid solution for BCC lesions (45). With the condition that the patients are selected properly, IVA may have an additional advantage with its modest side effects profile, compared to agents, such as chemotherapeutics, Smo-inhibitors or immunotherapies (46-48). However, at the time there were no studies to address the effects of high-dose I.V. ascorbic acid on BCCs.

2. Objectives

2.1 Project I.

Our aim was to evaluate the outcome of vismodegib therapy in our patients and to compare it with the literature. We reviewed the efficacy of vismodegib by evaluating CR, PR and ORR. We assessed the efficacy of vismodegib therapy on patients with or without comorbidities, the latter included any malignancies. Our additional goal was to evaluate whether vismodegib had any effect on these co-existing malignancies. After classifying and grading side effects associated with vismodegib treatment we aimed to compare our results with those in the literature. We also aimed to evaluate the efficacy of management options that can be utilized to alleviate or eliminate side effects of vismodegib. In addition, we attempted to assess whether unwanted and unsupervised discontinuation of vismodegib, due to unbearable side effects, had an influence on the development of secondary resistance. Lastly, we tried to compare if there is any difference between non-NBCCS and NBCCS patients in terms of development of drug resistance.

2.2 Project II.

Given that topically applied ascorbic acid showed efficacy on BCC, we set out to evaluate whether high-dose IVA therapy is effective either as a monotherapy or as an adjuvant therapy for BCC's which are otherwise uncurable. We assessed the efficacy of high-dose IVA and compared it to the results of the Smo-inhibitor vismodegib treatment. We examined whether high-dose IVA can be administered for long periods of time and in the presence of comorbidities. Furthermore, we assessed the mean and highest dose that could be administered via a peripheral vein or through a Port-A-Cath device. The side effect profile of high-dose IVA was also analysed and matched with that of Smo-inhibitor vismodegib.

2.3 Project III.

We aimed to test whether ascorbate, through its pro-oxidant properties can effectively kill *C. albicans* in vitro. As the mitochondrial respiration is a prerequisite for the formation of reactive oxygen species (ROS), we proposed that the electron transport chain (ETC)

might play a crucial role when ascorbate exerts its cytotoxic effect. We have assumed that the inhibition of the mitochondrial respiration either impairs the killing potential of ascorbate, or on the contrary it potentiates its toxic effect through the enhanced production of H_2O_2 (49). We evaluated the final effect of the inhibition of ETC with the usage of antimycin A. We also aimed to assess the effect that the concentration of Fe^{2+} can exert on the killing potential of ascorbate.

3. Materials and Methods

3.1 Project I.

Data collection

In this project clinical data of 11 laBCC patients were analysed retrospectively. Patients with or without NBCCS were included. They were all treated in our department with vismodegib between March 2013 and September 2017. The therapeutic effect was evaluated by monitoring the following parameters: diameter of the largest tumor, sum of the diameter of the lesions and number of tumors. Side effects were registered and graded, and we also gathered information on data of the therapeutic options to relieve or alleviate them. We gathered all data for efficacy and side effects from the medical documentation. Clinical photographs have been also taken regularly.

Statistical analysis

We performed statistical analyses using Graphpad Prism version 7.00 (Graphpad Software Inc, CA, USA). Data was tested using the Student's t-test and Kaplan-Meier analysis as suitable. Graphs display arithmetic means and error bars represent standard deviations (SD). The statistically significant value of p was considered <0.05.

3.2 Project II.

Design, eligibility criteria and patient enrolment

The high-dose IVA clinical trial was conducted at our department, the Department of Dermatology, Venereology and Dermatooncology, Semmelweis University, as a single center trial. The Regional Committee of National Science and Research Ethics (TUKEB 80/2010) and the National Institute for Quality- and Organizational Development in Healthcare and Medicines (39.798/56/09) approved the off-label use of ascorbate. We performed the study in accordance with the ethical standards by the Declaration of Helsinki, its further amendments or comparable ethical standards. Patients, who met the inclusion and exclusion criteria (Table 1.), were considered eligible and recruited for high-dose IVA therapy. All patients in the study group were diagnosed with laBCCs, they were not suitable for surgical excision or radiation, and at the time of the study no other treatment option, including vismodegib were available. The subjects could be

selected for the study regardless their NBCCS status. All patients gave their informed consent to the study.

Table 1.: Inclusion and exclusion criteria

Inclusion criteria	Exclusion criteria
Histologically confirmed locally advanced BCC	G6PHD enzyme deficiency
≥18 years of age	History of chronic heart failure
Patient not amenable to radiation, surgical or other available therapies	History of renal disease, evidence of kidney stones
Patient denied radiation, surgical or other available therapies that would lead to severe dysfunction and/or disfiguration	History of liver disease
Patient did not receive any treatment for BCC ≥4 weeks prior to IVA therapy	Other malignancies
ECOG status <= 2	Pregnancy or lactation
Normal renal function, GFR ≥60ml/min, serum creatinine level <120 μmol/l	
Normal liver function, total serum bilirubin ≤ 15 mg/L; AST <45U/L, ALT <55 U/L	

Treatment protocol

We administered 1.8 g/kg body weight IVA per each infusion with doses ranging from 75 to 175 g. After a four-week dose escalation cycle it was administered three times a week according to previous studies (47). Occasionally, due to other medical conditions unrelated to IVA therapy, we had to suspend treatments temporarily. These periods were later compensated by increased frequency of treatment in the following weeks. To safely administer the highly concentrated solution of ascorbate a Port-A-Cath device was used, as high osmotic effect might harm peripheral veins.

The high-dose IVA infusions were formulated from concentrated ascorbate solutions at the Department of Pharmacology of the Semmelweis University. Each vial of 50 ml consisted of 25 g ascorbic acid (500 mg/ml) buffered to pH 5,5-7, as described before (47). These vials were diluted in 1000 ml Ringer's lactate infusion and then carefully administered for 3 hours. Due to the photosensitivity of ascorbate, it was necessary to protect infusions from light during administration.

Evaluation of study outcome

For each patient at the baseline evaluation we chose one to six target lesions to monitor them monthly using digital photography and image analysis. Imaging techniques, as magnetic resonance imaging (MRI) and computer tomography (CT) scan were obtained, if needed, to give further data of changes in tumor volumes. So that to assess the response to the therapy, we adapted guidelines of the Response Evaluation Criteria in Solid Tumors (RECIST v.1.1) (50). The disappearance of all lesions was declared as complete response. Partial response was referred to the >30% value of decrease in sum of all longest diameters of lesions monitored. Development of a new tumor and/or an unequivocal escalation in overall disease status were defined as progressive disease (PD). At least 20% increase in sum of all longest diameter of target lesions was also specified as PD. Cases where the decrease in the sum of all longest diameters did not qualify for CR or PR, nor the criteria of PD is fulfilled we determined to stable disease (SD). We utilized Digimizer image analysis software v. 4.3 (MedCalc Software, Ostend, Belgium) to measure the longest diameter of each target lesion. The sum of the longest diameter of all target lesions from a patient gave the value of the cumulative target lesion size. The mean lesion size of all target lesions in each patient were also determined.

Histopathological examinations

Before the beginning and after IVA treatment tumor biopsy samples were collected in case of patient 1 and 2. In case of patient 3 and 4 an initial biopsy was obtained before treatment, but they did not consent to the collection of another, follow-up biopsy. We could collect additional tissue samples from tumors during treatment from patient 1, as she had numerous tumors with relatively great tumor sizes and outstanding compliance.

The 10% formalin-fixed and paraffin-embedded biopsy samples were stained with HE from all patients. Additional samples from patient 1 were used for immunohistochemistry evaluation. We attempted to assess the degree of vascularization in two different subtypes (micronodular, adenoid) of BCC in patient 1. In order to that monoclonal mouse anti-CD31 (PECAM-1, clone: 89C2, Cell Signaling, MA, USA) staining was performed.

3.3 Project III.

Materials

All chemicals for this study were purchased from Sigma-Aldrich, (St. Louis, MO) unless otherwise defined. Depending the experimental setup, the L-ascorbic acid was diluted and dissolved in phosphate buffered saline (without Ca^{2+}/Mg^{2+}) (PBS), PBS with D-(+)-glucose (20g/L), YPG (yeast extract-peptone (30g/L) (ForMedium Ltd), YPD (BD-DifcoTM, yeast extract 10g/L; peptone 20g/L; dextrose 20g/L), glycerol (38g/L) media. Solutions of ascorbic acid were prepared and buffered with $NaHCO_3$ (Fisher Scientific, Pittsburgh, PA) to neutralize pH. In all experiments the final concentration of ascorbate was set to 90 mM. Antimycin A (extracted from streptomycin sp.) was dissolved in ethanol solution and further on diluted to 10 μM concentration. The iron chelator 2,2´-bipyridyl (bipyridyl) was diluted to 500 μM.

Cell culture

CEC 749 strain of *C. albicans* was used in this experiment (51). It was grown on YPD agar and subcultured in liquid YPD medium in a shaking incubator routinely at 30°C (New Brunswick Scientific, Edison, NJ). In the experiments we obtained log phase cultures acquired from reculturing stationary overnight cultures. All broth cultures were centrifuged at 3,200 rpm for 10 min (centrifuge 5417 C; Eppendorf, Hamburg, Germany) and then re-suspended in PBS solution. Use of optical density (OD570 of 0.65) we adjusted the concentrations to give an average cell density of 10^7 CFU/mL.

Experimental design

We used 35x10mm diameter Petri dishes (BD Falcon) containing approximately 3X107 cells, the growth media was 3 mL. Cells were analysed in PBS media. At 157rpm the cells were shaken at 37°C. Two aliquots (10μL each) were withdrawn from the media at each time point. Samples were withdrawn at time points (0, 10, 20, 30, 60, and 90 minutes). At each time point aliquot was plated on PBS media. Furthermore, 4 additional 10-fold dilutions were made and then plated on agar plates. We have been incubating plates between 24-48h at 30°C. The cell viability was evaluated by colony counting method in all experiments. In another setup *C. albicans* cells were refreshed for 4h in YPD (BD-DifcoTM, yeast extract 10g/L; peptone 20g/L; dextrose 20g/L), with antimycin A (10μM) added or not after 1h. Antimycin A is a metabolic inhibitor of the electron

transport chain (49). The cells were washed, re-suspended and shaked in the incubator (157rpm, 37 C) with or without ascorbate in either PBS or YPD. The aliquot samples were withdrawn at the same time points as mentioned before. To evaluate whether the pathomechanism that ascorbate kill *C. albicans* cells is dependent on the presence of Fe^{2+} we used an iron chelator, called bipyridyl (500μM) dissolved in PBS. We re-suspended cells and bipyridyl was added, and incubated with shaking (157rpm, 37°C) and the aliquots were withdrawn as before (0, 10, 20, 30, 60, and 90 minutes).

Statistics

Experiments were repeated at least 3 times. Data points are means and error bars are standard deviations. Means were compared for significance ($p<0.05$) by one-way ANOVA and Bonferroni post-hoc test.

4. Results

4.1 Project I.

4.1.1 Efficacy of vismodegib therapy

The mean age of all patients was 73±15 years, including 9 female and 2 male patients. 7 patients had laBCC without NBCCS and in 4 cases laBCC developed due to NBCCS. Based on the NBCCS vs. non-NBCCS status, patients without NBCCS had one laBCC in general, except patient 1 and 6 who had multiple BCCs. PTCH1 mutation, loss of function type, was revealed in 3 out of 4 NBCCS patients. 67.7% of all lesions were localized in the sun exposed body surfaces. Involvement of non-exposed parts of the body was significantly more common among NBCCS patients. Almost all patients had been treated with at least two other treatment modalities before. The choice of treatment in order of preference prior to Smo-inhibitor vismodegib was surgical excision, radiotherapy followed by cryotherapy. Only one patient did not receive any prior treatment. Almost all patients, except one, had a coexisting benign tumor or some form of malignancy other than the BCC, such as polycytemia vera, colon, prostate or bladder cancer (Table 2.). During vismodegib treatment no deterioration in the status of these cancers could be observed.

Table 2: Status of laBCCs, accompanying benign tumors or malignancies and therapies received prior to treatment with vismodegib

	Sex	Age	Clincal findings	Number of lesions before treatment		Other tumors	Treatment before vismodegib
				Sun exposed areas	Not exposed		
Patient 1	Male	84	laBCC	14 (32.55%)	29 (67.45%)	Polycytemia vera	Surgical excision, electrocauterization, cryotherapy
Patient 2	Male	78	laBCC	1 (100%)	0 (0%)	Prostate cancer	Surgical excision, radiotherapy
Patient 3	Female	85	laBCC	1 (100%)	0 (0%)	Meningiome	Surgical excision
Patient 4	Female	80	laBCC	1 (100%)	0 (0%)	Morbus Bowen	Surgical excision, cyrotherapy
Patient 5	Female	68	laBCC	1 (100%)	0 (0%)	-	Radiotherapy, plastic surgery, CO2 laser
Patient 6	Female	89	laBCC	2 (100%)	0 (0%)	Colon carcinoma	Surgical excision, cryotherapy
Patient 7	Female	84	laBCC	1 (100%)	0 (0%)	Myoma uteri, meningiome	Radiotherapy, surgical excision
Patient 8	Female	53	NBCCS	38 (71.7%)	15 (28.3%)	Angiomyolipoma renis	Surgical excision, radiotherapy, cryotherapy, farmacological: acitretin, imiquimod, CO2 laser
Patient 9	Female	58	NBCCS	36 (81.82%)	8 (18.18%)	Meningioma	Surgical excision, radiotherapy, cryotherapy
Patient 10	Female	43	NBCCS	48 (73.85%)	17 (26.15%)	-	Surgical excision, farmacological: acitretin
Patient 11	Female	81	NBCCS	6 (75%)	2 (25%)	Bladder cancer	-

Prior to vismodegib treatment the mean of the diameters of the largest lesions was 5.18±4.25 cm (Fig. 3A) and the average number of lesions was 20±25.47 (Fig. 3B).

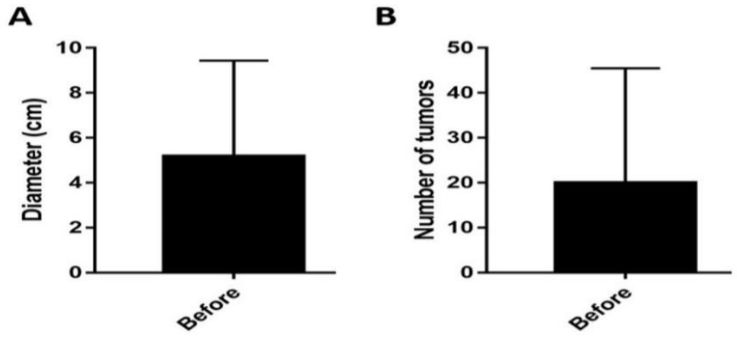

Figure 3.: A: the mean of diameters of the largest lesions before initiation of vismodegib therapy, **B:** average number of lesions before vismodegib.

When a comparison is made based on the number of lesions, a remarkable difference is observed between non-NBCCS and NBCCS groups (7±15.81 vs. 43 ±24.5; non-NBCCS vs. NBCCS respectively; p=0.016). However, for the average diameter of the biggest lesion no significant difference can be observed (5.3±4.7 cm vs. 4.9±3.9 cm; non-NBCCS vs. NBCCS respectively; p=0.89) (Fig. 4.)

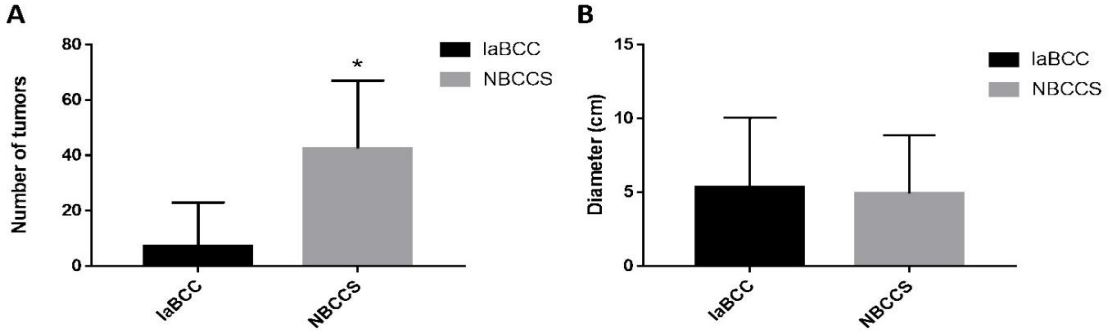

Figure 4.: A: the average number of lesions in NBCCS patients was significantly higher when compared to that of laBCC non-NBCCS patients, **B:** the mean of diameters of the largest tumors did not show significant difference between the two groups of patients (*: p<0.05 laBCC vs. NBCCS).

The Smo-inhibitor treatment was administered for 16±15.69 months for the 11 patients who participated in this study. The drug was administered for 20±23.17 months for patients with NBCCS and for 14±10.89 months in cases of laBCC without NBCCS. When the period from the time of initial response until documented tumor progression was measured, no difference was observed between the two patient groups (2±0.69 vs. 2±0.82

months; laBCC vs. NBCCS respectively; p=0.76). A CR was achieved in 3 patients, and after the discontinuation of vismodegib no relapse could be observed (Fig. 5).

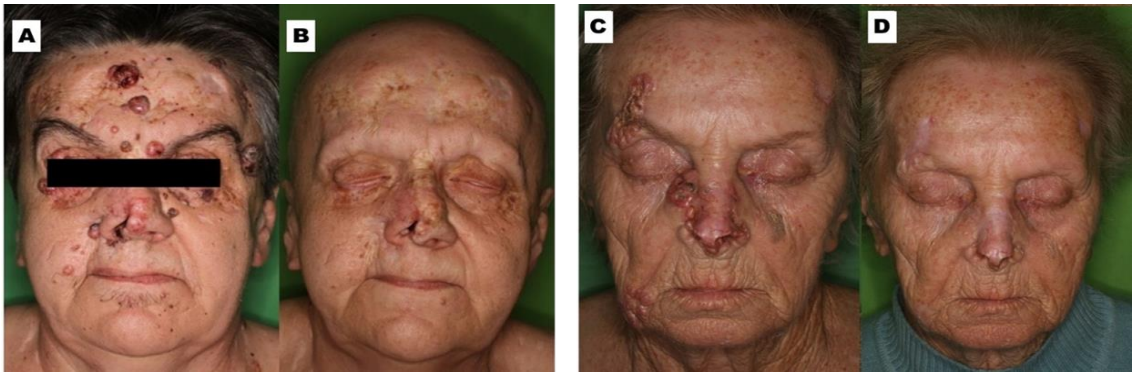

Figure 5.: Representative pictures of 2 patients who showed a complete response (CR) to vismodegib **A**: Patient 9 before treatment, **B:** Patient 9 after 47 months of treatment. **C**: Patient 11 before treatment, **D:** Patient 11 after 11 months of treatment.

Additional 3 patients showed excellent improvement, but afterwards they were deceased due to conditions unrelated to laBCCs and drug-therapy. The treatment was temporarily suspended due to intolerable side effects in the case of two non-NBCCS patients (patient 2 and 3). Both patients initially showed a good therapeutic response, but when vismodegib therapy was restarted the efficacy became gradually lower and subsequently lost, and their condition worsened. Changes of the clinical status of patient 3 is shown on Fig. 6..

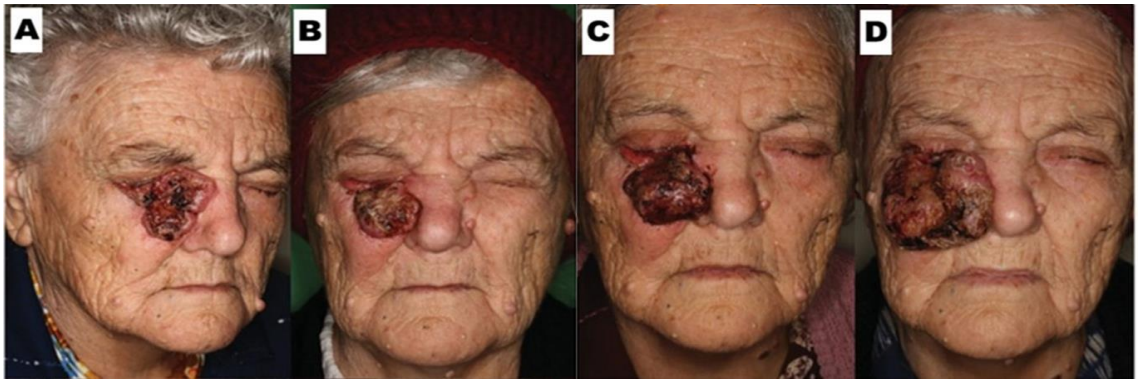

Figure 6.: Clinical status of patient 3 A: before vismodegib treatment, **B:** after 3 months of vismodegib therapy when a PR was observed, **C:** after a temporary suspension and then re-initation of treatment – approximately 5 months post-therapy with moderate progression, **D:** after 8 months loss of efficacy of vismodegib treatment with significant deterioration of the tumor.

Other patients showed notable response to treatment, but not a CR. Clinical status of one of these patients is shown in Fig. 7..

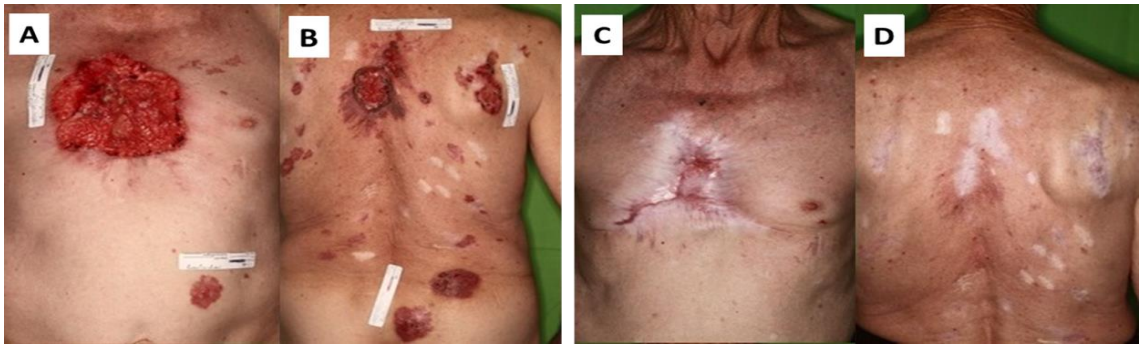

Figure 7.: A-B: clinical pictures of patient 1 before the initation of vismodegib therapy, **C-D:** after 15 months period of time of vismodegib treatment.

By the end of the follow-up period the average number of lesions (20±25.47) decreased to 5.5±16.52. We measured the tumor shrinkage according to change in the size of the longest diameter, as we considered that this parameter was proportional to the total tumor burden. The average of the diameter of the largest tumors was significantly reduced after treatment (2.7±2.7 cm; 3.1±2.2 cm vs 6.1±10.5 cm; laBCC vs NBCCS respectively; p=0.47) (Fig. 8.).

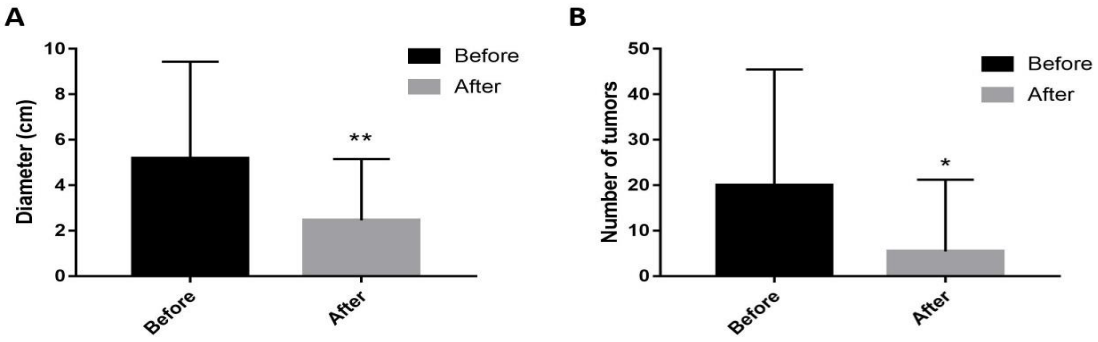

Figure 8.: A: the average largest diameter of the largest lesions significantly decreased after treatment, **B:** the total number of tumors is significantly reduced after vismodegib therapy. (*: p<0.05 before vs. after; **: p<0.01 before vs. after)

For all patients, the treatment outcome and result of efficacy data in detail is shown in Table 3.

Table 3. Treatment outcome and efficacy data of vismodegib treatment

	Duration of treatment (months)	Outcome	Number of tumors		Diameter of the largest lesion (cm)		Duration of treatment until initial response
			before treatment	after treatment	before treatment	after treatment	
Patient 1	15	improvement	43	2	13	5.8	2
Patient 2	16	improvement followed by deterioration	1	1	0.8	2	3
Patient 3	15	deceased	1	1	8	10.3	3
Patient 4	3	complete remission	1	0	0.3	0	2
Patient 5	35	improvement	1	1	1.5	3.6	2
Patient 6	5	deceased	2	1	5.8	1	1
Patient 7	6	improvement	1	1	8	4	2
Patient 8	2	deceased	53	n/a	9.4	18.2	2
Patient 9	54	complete remission	44	0	2.3	0	2
Patient 10	13	improvement	65	n/a	1	n/a	1
Patient 11	11	complete remission	8	0	7	0	3

4.1.2 Assessment of side effects of vismodegib treatment

4.1.2.1 Types and grades of side-effects

The most common vismodegib-related side-effects were muscle cramps, weight loss, dysgeusia and alopecia. These adverse events first appeared at a mean of 6.45±3.45 weeks from the beginning of the therapy (7±3.94 vs. 5±2 weeks; laBCC vs. NBCCS respectively; p=0.31). The most common side effect was weight loss and it was seen in case of 9 patients. This was followed by dysgeusia in 8 patients. Muscle cramps have developed in 7 and alopecia appeared in case of 6 patients. The side-effects related to therapy developed in both NBCCS and non-NBCCS groups. All, except one patient, noticed more than one side effect, and in our cohort of patients no Grade 4 adverse event was recognized. The severity of the side effects was Grade 2 in 29% percent of all side effects, and Grade 3 was observed in 6 patients. Grade 1 level adverse events were detected in the case of the other five patients. We did not find any significant difference in the number of patients experiencing Grade 2 and Grade 3 side effects between non-NBCCS and NBCCS patient groups (Table 4).

Table 4.: Types, distribution and severity of side-effects due to vismodegib

	Adverse events					First appearence of adverse events
	Alopecia	Muscle cramps	Dysgeusia	Weight loss	Other	
Patient 1	Grade 1	Grade 2	Grade 1	Grade 3	-	6 weeks
Patient 2	-	Grade 1	-	Grade 1	-	12 weeks
Patient 3	-	-	Grade 1	Grade 1	-	12 weeks
Patient 4	Already existing complaint	-	-	Grade 1	Nausea (grade 1)	8 weeks
Patient 5	Grade 2	Grade 3	Grade 1	Grade 1	Numbness of toes (grade 1)	2 weeks
Patient 6	Grade 1	Grade 1	Grade 1	Grade 3	GERD (grade 1), nausea (grade 1), malaise (grade 1)	3 weeks
Patient 7	-	-	Grade 1	Grade 1	-	8 weeks
Patient 8	-	-	Grade 1	-	-	8 weeks
Patient 9	Grade 2	Grade 3	Grade 2	Grade 1	GERD (grade 1), fatigue (grade 1), nausea (grade 1)	4 weeks
Patient 10	Grade 2	Grade 1	Grade 2	-	Change in bowel functions (grade 1), continuous nausea (grade 2), intrequently vomiting (grade 1)	4 weeks
Patient 11	Grade 1	Already exsisting, worsened after the administration (grade 2)	-	Grade 1	Indigestion (grade 1)	4 weeks

4.1.2.1. Management of side-effects

We attempted to find a way to alleviate grade 2 and 3 muscle cramps with the use of combination of tizanidine (α2-adrenergic agonist) and tolperisone (central acting skeletal muscle relaxant) and achieved moderate success. On the contrary, tizanidine and amlodipine, a combination that has been commonly reported in the literature (24), did not exert any marked improvement. On the other hand, magnesium and calcium supplementation was sufficient to alleviate grade 1 muscle cramps. In female patients, to manage alopecia, we have applied topical estradiol and prednisolone lotion without any notable effect. After completion of vismodegib treatment, hair regrowth of varying degree was observed for all patients after. In cases of reduced appetite and subsequent weight loss, oral nutritional supplements were provided. As a result, the rate of weight loss initially slowed down. However, due to further decrease in body weight at later stages, the treatment had to be discontinued in case of two patients. In order to prevent dysgeusia, specific dietary instructions were provided with only limited success.

4.2 Project II.

4.2.1 Efficacy of high-dose IVA

In this single centre clinical trial 6 patients were screened from our oncology outpatient department. From those, 4 patients could be enrolled, and the 2 patients were excluded during the screening period. One patient had to be excluded due to history of renal stones. The other could not be included for compliance issues. Three out of the selected four patients had NBCCS. The mean age was 62.3 ± 16.2 years (range: 47-83 years) for the four enrolled patients. For further patient demographics and clinical data see Table 5.
Patients who were treated with high-dose IVA, had an average of 41.25±51.7 lesions (range: 1-114). We assessed the efficacy of treatment based on follow up of a total of 18 target lesions. The mean lesion size of the target lesions was 27.95±31.90 mm (range: 5-108.5 mm). Regarding the localization of the lesions, 72% of the tumors were on the head and neck region, 17% on the trunk and the rest were on the extremities. The high-dose IVA therapy was administered for a mean duration of 42 ± 23.6 weeks (Table 6).

Table 5.: Patient demographics and clinical data (NIDDM: non-insulin dependent diabetes mellitus, AF: atrial fibrillation, HT: hypertension)

	Patient 1	Patient 2	Patient 3	Patient 4	Mean, SD
Age (years)	47	67	83	52	62.25±16.23
Sex	F	M	M	M	
Patient history	NIDDM, MI, AF, Fibrotic type pseudotumor of small bowel	NIDDM, HT	HT	none	
Fitzpatrick skin type	Type I	Type II	Type II	Type II	
Age at first onset of disease (years)	24	53	N/A	17	
BCNS	Yes	No	Yes	Yes	
Palmar pitting	Yes	No	Yes	Yes	
Jaw cysts	No	No	No	Yes	
Falxcerebri calcification	Yes	No	Yes	Yes	
Minor BCNS criteria (skeletomuscular system abnormalities, medulloblastoma, intestinal tumor, ovarian fibromas, etc.)	Yes	No	Yes	No	
Previous excessive sun exposure	No	Yes	Yes	Yes	
Location of BCC lesions	scalp, face, neck, ear, trunk	orbit, lower eyelid, intrasinusoidal mucous membrane	nose, forehead, ear, back	scalp, face, neck, trunk, upper extremities	
Number of BCC lesions	42	1	8	114	41.25 ±51.7
Previous treatment modalities	Surgery, CO_2 laser, cryotherapy, imiquimod, acitretin, PDT	Radiotherapy (patient denied surgery or enucleation)	Surgery, radiotherapy	Surgery, cryotherapy, isotretinoin, acitretin, PDT, intralesional INF	

Table 6.: Types, localization and size of treated lesions and duration of treatment

	Patient 1	Patient 2	Patient 3	Patient 4	Mean, SD
Number of target lesions	6	1	5	6	4.5±2.3
Location of target lesions	Scalp, periauricular, temporal, frontal and mental area	Orbit, lower eyelid, intrasinusodial mucous membrane	Nose, forehead, ear	Face, chest, right shoulder, right upper arm, right and left suprascapular area	
Subtypes of target lesions	nodular-micronodular, adenoid	infiltrative	infiltrative	nodular, pigmented, superficial	
Cumulative initial size of target lesions (mm)	301,2	88,1	43,1	70,7	125.8±118.4
Duration of treatment (week)	76	26	26	40	42±23.6

We administered 1.8 g/kg body weight IVA per each infusion with doses ranging from 75 to 175 g as described in Materials and Methods section. In case of patient 4, the patient refused the implantation of a Port-A-Cath device, therefore 1.3 g/kg body weight i.e. 100 g ascorbate was given per infusion. This was the maximum dose that the patient could tolerate via peripheral vein administration. For patient 3 initially the Port-A-Cath could not be installed. For this first 12-week period we reduced the dose to 1.1 g/kg body weight i.e. 75 g per occasion (for detailed description of dosage given see Table 7).

Table 7.: Treatment duration and dosage specification

	Patient 1	Patient 2	Patient 3	Patient 4	Mean, SD
Duration of treatment (week)	76	26	26	40	42±23.6
Number of treatments/week	2-4	3	3	1-2	
Number of Treatment Sessions	173	72	75	49	92.2±55.1
Maximum interval between two subsequent treatments (weeks)	5	1	1	6	
Usage of port-a-cat device	Yes	Yes	Yes (after 12 weeks of peripheral vein administration)	No (administered via peripheral vein)	
Maximum dose of ascorbic acid / treatment	1.8 g/kg; 175 g	1.8 g/kg; 125 g	1.1 g/kg, 75 g (first 12 weeks); 1.8 g/kg, 125 g (after 12 weeks)	1.3 g/kg, 100 g	
Cumulative dose of ascorbic acid	29150 g	8970 g	7039 g	4800 g	

In case of lesions that showed response to the therapy, we observed an average 4-16% reduction in size. However, some tumors progressed and not responded to therapy (Table 8.). In 83% of all target lesions we could detect some degree of a benefit (partial and stable response). 27% of all tumors, that responded to therapy, partial response was seen whereas the remaining 73% displayed stable response (Table 9.). In case of patient 1, an adenoid type BCC, which was scored a stable response per criteria, did not change in size throughout the entire study. This lesion showed neither regression, nor progression. No patients developed any detectable new lesions. The overall treatment response assessment showed stable disease for 75% of the patients (3) and in 25% (1) progressing disease was observed (Table 9.)

Table 8.: Changes in target lesion size after high-dose IVA treatment

Variable	Target lesion location	Average target lesion sizes before treatment (per patient, mm)	Cumulative target lesion sizes before treatment (per patient, mm)	Average target lesion size after treatment (per patient, mm)	Cumulative target lesion sizes after treatment (per patient, mm)	% Change in target lesion size after treatment	Average % change in target lesion size after treatment (per patient)
Patient 1		50.2	301.2	42.3	253.5		-0,16
Lesion 1	left occipital					-0,23	
Lesion 2	right occipital					-0,34	
Lesion 3	forehead glabella					-0,25	
Lesion 4	right temporal					-0,34	
Lesion 5	right preauricular					0,32	
Lesion 6	mental area					0,01	
Patient 2		88.1	88.1	74.9	74.9		-0,15
Lesion 1	right eye					-0,15	
Patient 3		8.6	43.1	7.3	36.4		-0,16
Lesion 1	nose					-0,48	
Lesion 2	right forehead					0,29	
Lesion 3	left forehead					0,27	
Lesion 4	nose					0,12	
Lesion 5	left ear - tragus					-0,97	
Patient 4		11.8	70.7	11.3	67.8		-0,04
Lesion 1	right infraorbital					-0,09	
Lesion 2	right upper arm					-0,12	
Lesion 3	left suprascapular					0,06	
Lesion 4	right suprascapular					-0,12	
Lesion 5	right shoulder					0,15	
Lesion 6	left chest-mammary area					0	
Mean		39.7	125.8	34	108.2		-0.13
SD		37.4	118.4	31.5	98.3		-0.06

Table 9.: Overall treatment response to high-dose IVA therapy

Variable	Target lesion location	Target lesion response/overall target lesion response	New lesions	Overall response
Patient 1		**STABLE**	0	**STABLE**
Lesion 1	left occipital	Stable		
Lesion 2	right occipital	Partial		
Lesion 3	forehead glabella	Stable		
Lesion 4	right temporal	Partial		
Lesion 5	right preauricular	Progression		
Lesion 6	mental area	Stable		
Patient 2		**STABLE**	0	**PROGRESSION***
Lesion 1	right eye	Stable		
Patient 3		**STABLE**	0	**STABLE**
Lesion 1	nose	Partial		
Lesion 2	right forehead	Progressed		
Lesion 3	left forehead	Progressed		
Lesion 4	nose	Stable		
Lesion 5	left ear-tragus	Partial		
Patient 4		**STABLE**	0	**STABLE**
Lesion 1	right infraorbital	Stable		
Lesion 2	right upper arm	Stable		
Lesion 3	left suprascapular	Stable		
Lesion 4	right suprascapular	Stable		
Lesion 5	right shoulder	Stable		
Lesion 6	left chest- mammary area	Stable		

*(*unequivocal increase in overall disease status due to intrasellar invasion)*

Representative clinical images of lesions before and/or during therapy is shown for patient 2 and 3 in Fig 9..

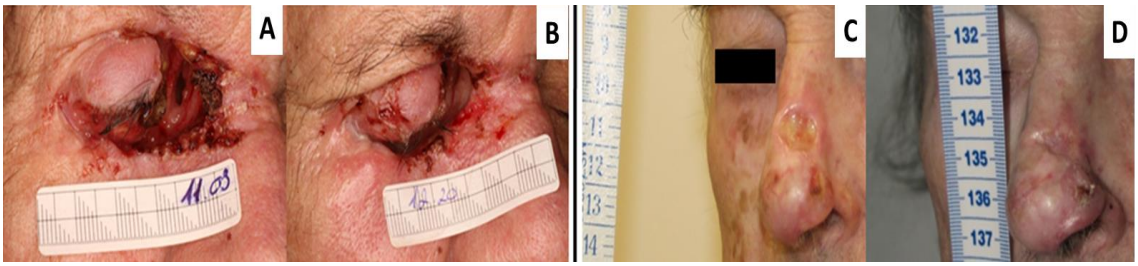

Figure 9.: A: laBCC infiltration of the nasal and periorbital regions at week 9 **B:** and at week 16 of IVA treatment in patient 2. **C:** target BCC lesion in the nasal region before IVA therapy at week 0, **D:** after IVA therapy at week 26 in patient 3.

Representative images of lesions of patient 1 before and after IVA therapy are shown in Fig. 10.

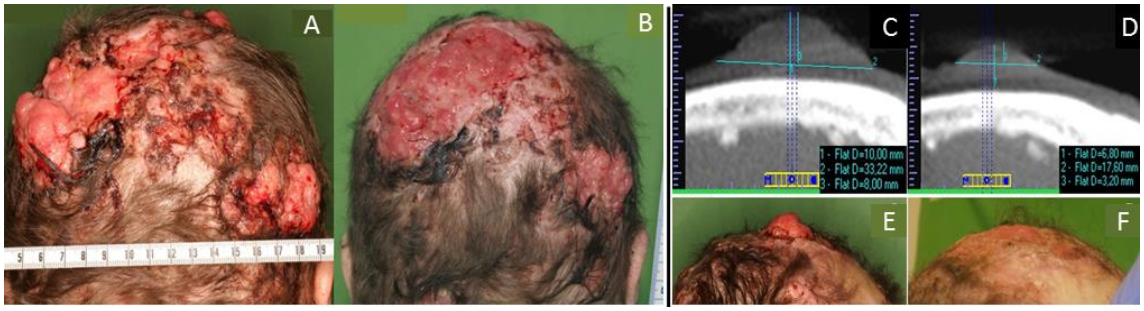

Figure 10.: A: laBCC of patient 1 before high dose IVA treatment at week 0, **B:** and at week 75, respectively. **C-D:** CT scans and **D-F:** clinical photos of a target lesion on the scalp of patient 1 before (week 0) and after (week 75) IVA therapy.

Follow-up skin biopsy taken from the nasal root region of patient 2 showing a tumor-free scar tissue is displayed below (Fig. 11).

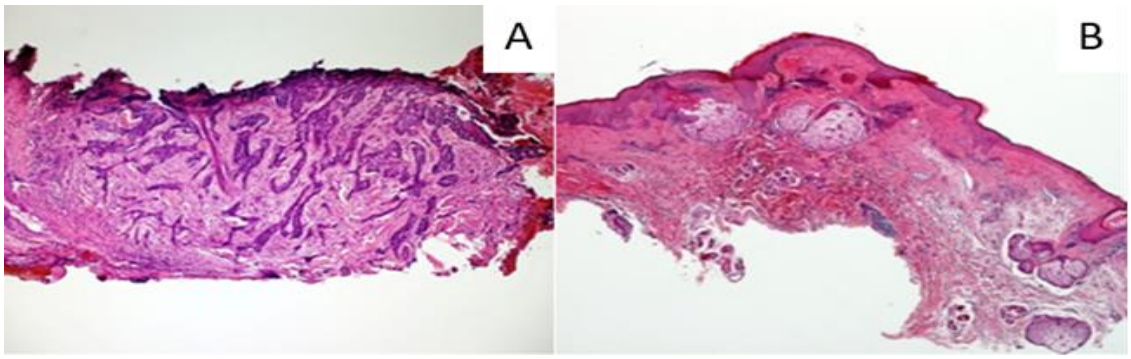

Figure 11.: A: hematoxylin and eosin (HE) staining of a tissue sample from the nasal region of patient 2 before the initiation of high-dose IVA therapy, infiltrative type BCC , **B:** HE staining of a tissue biopsy sample from the same region at the end of high-dose IVA treatment, scar tissue.

Despite all our efforts in patient 1 and patient 3 worsening of some lesions could not be completely prevented. Therefore, we have decided to switch to vismodegib, as it became available as in a phase III. clinical trial setting. Thereafter patient 1 died of sepsis caused by urinary tract infection, irrespective of vismodegib therapy. We also introduced vismodegib for patient 3, and later on he died of glioblastoma multiforme, which was also unrelated to Smo-inhibitor treatment. In case of patient 2, during IVA therapy we could measure the decrease of the longest diameter of the tumor on the skin surface by 13%. For that it could be rated as stable disease, but still an unequivocal intrasellar invasion was detected after 4 months of treatment. We continued the IVA therapy and the progression could be slowed down. Due to the worsening of the patient's general

condition we discontinued the IVA therapy. Palliative radiotherapy was initiated to manage the intrasellar invasion. However, the patient died soon after due to complications of irradiation therapy. Patient 4 dropped out from the study and we could obtain further data about his condition.

4.2.2 Side-effects of high-dose IVA

We did not observe any significant adverse events, including nephrolithiasis, during IVA treatment. Only some well-tolerable and mild side-effects developed, such as an occasional nausea (Grade 1) in patient 1. During the administration of IVA into a peripheral vein, patient 3 and patient 4 indicated a mild burning sensation (Grade 1).

4.2.3 Assessment of microvessel density in different BCCs by CD31 staining

The microvessel density refers to the vascularisation of a tumor and it strongly correlates with CD31 endothelial cell marker CD31 (52). It has been studied that in aggressive subtypes of BCCs the microvessel density is greater when compared to lesions with slower rate of growth (53, 54). Adenoid BCC is generally considered an indolent form, while micronodular BCC is a subtype with more destructive features and less favorable clinical outcome (55). In case of patient 1 with multiple lesions, most micronodular have shown improvement during IVA therapy, whereas adenoid type lesion has not responded to the therapy (Fig. 12).

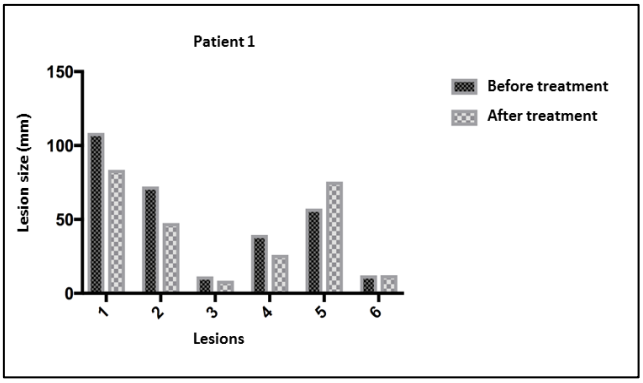

Figure 12.: largest diameter of each tumor of patient 1 before and after IVA therapy. Subtypes were distributed as the following: lesion 1 (micronodular), lesion 2 (micronodular), lesion 3 (nodular), lesion 4 (micronodular), lesion 5 (micronodular), lesion 6 (adenoid).

In order to reveal the differences of microvessel density between the two type of lesions an immunostaining with CD31 on one adenoid and one micronodular biopsy specimen of patient 1 have been done. We recognized a remarkably lower level of microvessel density in the adenoid subtype compared to the micronodular type lesion (Fig. 13).

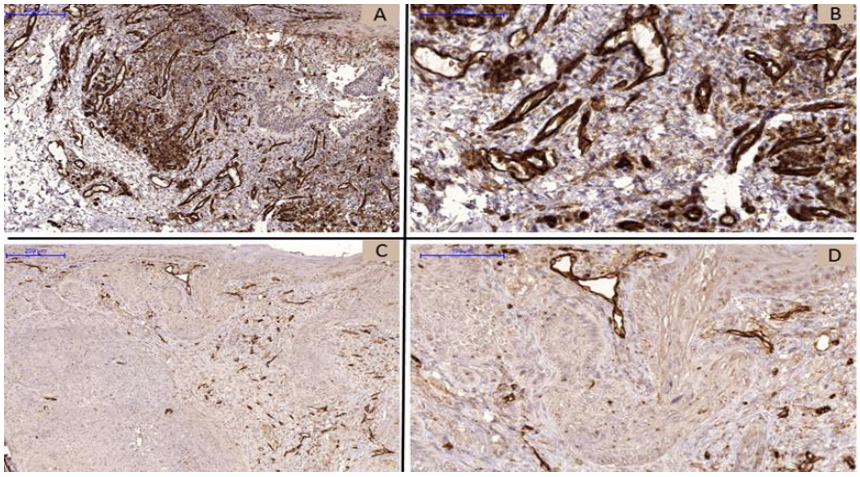

Figure 13.: A: micronodular BCC in patient 1 showing high microvessel density in magnification 140X, **B:** magnification 400X. **C:** a separate lesion of patient 1, i.e. an adenoid BCC with low microvessel density magnification 140X, **D:** magnification 400X (brown color refers to CD31 positivity).

4.3 Project III.

4.3.1 Ascorbate could exert its killing potential in PBS growth media, and this effect strongly depends on Fe^{2+} concentration

Ascorbate could eradicate *C. albicans* when the cells were incubated and shaken in PBS at 37°C (after 90 min. > 5 logs killing). The use of iron chelator bipyridyl (500 µM) could inhibit the killing effect of ascorbate (>2 logs) at time-points 30 and 90 min (Fig. 14.). This may be explained by the reduced concentration of $HO^{\cdot}$, which is accumulated in the Fenton reaction catalysed by free Fe^{2+}.

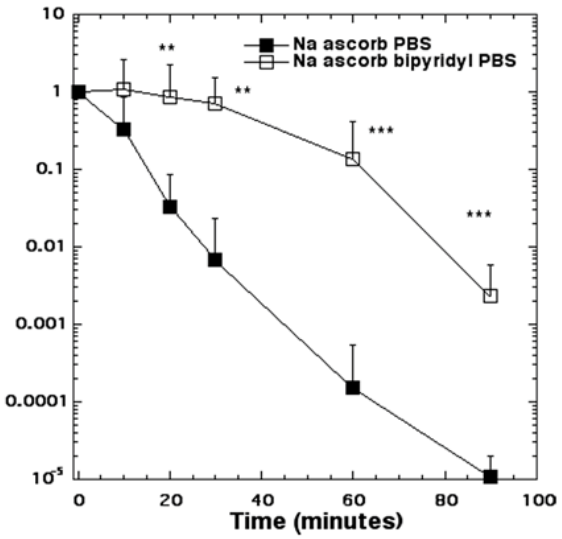

Figure 14.: time-dependent killing potential of ascorbate evaulated on C. albicans shaken in PBS at 37°C with 90 mM sodium ascorbate with or without addition of the free iron chelator 2,2-bipyridyl (500 µM). ** $p < 0.01$; ** $p < 0.001$ (40) (with permission)

4.3.2 The killing potential of ascorbate is increased with antimycin A

The inhibition of complex III in ETC in *C. albicans* cells with antimycin A increased the killing effect of ascorbate in PBS media (Fig. 15) (56).

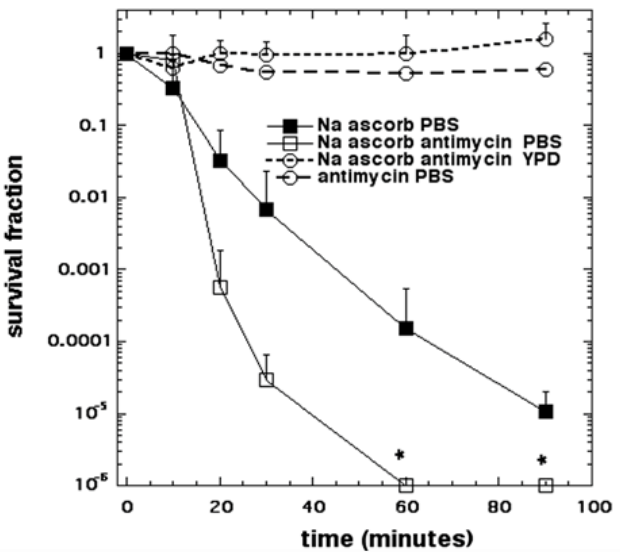

Figure 15.: killing effect of ascorbate was evaluated by time with *C. albicans* shaken in PBS at 37°C with 90 mM ascorbate, or in PBS or YPD with 90 mM ascorbate following treatment with complex III inhibitor antimycin A (10 µM) or with cells pre-treated with ETC inhibitor antimycin and shaken in PBS at 37°C in PBS as control.

5. Discussion

In our first project, we evaluated the Smo-inhibitor vismodegib treatment of laBCCs in 11 Hungarian patients with or without NBCCS in a single centre. Locally advanced BCC and hard-to-treat cases of NBCCS most commonly develop in the aging population. Elderly people with a high prevalence of other tumors and comorbidities are often excluded from clinical trials. Our study included patients with other malignancies and a variety of different comorbidities. As vismodegib is a rather new therapeutic option in oncology to treat BCC, existing data are mainly derived from clinical trials (57). Therefore, the experience with vismodegib with patients who suffer from coexisting malignancies and other accompanying diseases provide real-life data about the drug and its limitations. In case of Patient 1 the pre-existing polycytemia vera remained unchanged during the Smo-inhibitor treatment. Patient 2 also had one other malignancy: prostate cancer. He received vismodegib treatment with the ongoing combination therapy of phase II trial (NCT01163084) drug and a GnRH agonist for prostate cancer. We did not see any progression of his prostate cancer during vismodegib treatment. It has been shown that the Hh pathway has a significant role in the pathomechanism of prostate cancer (58). In accordance with this finding, vismodegib may have a beneficial effect in the therapy of prostate cancer (10). Patient 3 had a suspected lesion of meningioma for which reason previously he/she could not be enrolled into any clinical trial. We started vismodegib therapy and the lesion, confirmed by CT scan, did not progress for the time of Smo-inhibitor treatment. Patient 9 also had a meningioma that was diagnosed before the initiation of vismodegib therapy. We could achieve CR of laBCCs and did not observe any progression in meningioma. The pathomechanism of meningioma often involves disruption of the Hh pathway. Therefore, having the capability to regulate Hh pathway presumably gives us a possible chance to successfully treat malignant expansive meningeal tumors (59). However, in case of our patients, Smo-inhibitor vismodegib therapy did not show any efficacy on meningiomas.

We could demonstrate an ORR similar to those reported in earlier clinical trials, as 7 patients out of 11 showed CR or PR to vismodegib therapy (60). In our patient group we could or needed to administer therapy drug for 4.6±5.3 months. In certain cases patients did not comply with the treatment schedule due to intolerable and not successfully

managed side effects. Mainly due to the intolerable side effects 5 patients permanently discontinued vismodegib treatment. This rate was higher than published in the ERIVANCE BCC study, where 17% of laBCC patients discontinued the Smo-inhibitor therapy permanently as a result of intolerable adverse events (19).

In case of modern oncology treatments, such as target therapies, it is crucial to avoid drug resistance. Secondary (acquired) resistance is defined with a convincing initial effect of therapy followed by subsequent worsening of tumor condition and in case of Smo-inhibitors this type of resistance is more common in comparison to the primary (intrinsic) form. Mechanisms through which resistance to vismodegib develops include but are not limited to a mutation in the Smo, GLI2 amplification, upregulation of PI3 kinase pathway (29-31).

Since drug resistance has a higher chance to develop if the therapy is discontinued for any time, as it happened in case of patient 2, it is crucial to successfully manage the side-effects. When adverse events, such as severe muscle crumps, loss of appetite and alopecia cannot be well managed or prevented, several patients with the potential to benefit from the therapy may discontinue therapy either temporarily or permanently.

According to the literature both primary and secondary resistance can develop either in NBCCS or non-NBCCS patients (29-31). In the study of Chang et al., a resistance rate of 13% was observed in a non-NBCCS patients (30). In our retrospective analysis, in the group of patients without NBCCS 2 out of 7 acquired resistance after a temporary discontinuation of vismodegib, which is a higher rate compared to the previously mentioned study. In the same study in the NBCCS group 3 out of 5 patients showed secondary resistance to therapy drug (30). Conversely, we observed that patients with NBCCS did not develop any secondary resistance to vismodegib, even after temporary discontinuation of Smo-inhibitor drug. The main difference between the two subgroups could presumably be that NBCCS patients possess a germline mutation in PTCH1, and sporadic cases carry particular mutations of the HH pathway. It has also been hypothesized that tumors, previously treated with radiotherapy or chemotherapy, could more easily develop secondary resistance (31). Further evaluation of the molecular genetics of BCCs is necessary to understand and more successfully avoid the evolution of acquired resistance.

In our study, in line with the literature, the most common reason to temporarily or permanently discontinue vismodegib therapy was the severe side effects that could not be managed successfully (21). Vismodegib can have multiple harmful effects through the disruption of the Hh pathway. One of them is the partial inhibition of calcium channel activity in striated muscle, which is possibly the underlying pathophysiology of muscle cramps (24). In a clinical trial of 43 laBCC patients, calcium channel blocker amlodipine was given to manage muscle cramps with remarkable success (24). We also administered amlodipine in two cases; but it did not show any substantial benefit on muscle cramps. On the other hand, when we administered central muscle relaxants, tolperisone or tizanidine we were able to achieve some notable success. Considering that both central muscle relaxants and calcium channel blockers have an antihypertensive effect, the adjustment of the dose is of importance. As Hh pathway is paramount to hair follicle morphogenesis, alopecia is a predictable side effect. A previous trial revealed that 46-66% of patients treated with Smo-inhibitor vismodegib suffered from alopecia (25). Among our patients, 3 developed grade 1, 3 patients developed grade 2 alopecia. Topical lotion with prednisolone or estradiol did not show any effect in our experience. As minoxidil enhances hair growth, it may also be considered as an effective treatment strategy for patients experiencing hair loss due to vismodegib therapy (61). With the discontinuation of vismodegib alopecia is mostly reversible, however several months are needed for recovery. In rare cases permanent alopecia have been observed after vismodegib therapy (62). Alopecia can cause severe psychological issues, and subsequent compliance problems; so patients should be thoroughly informed.

Loss of weight is also a frequent side effect, and, in a prospective study it was measured to 16-46% and also to our investigation, where it the most common adverse event involving 9 patients (63). The explanation behind the weight loss can be multifactorial, including the hypothesis that vismodegib interferes with the AMP kinase signalling pathway such that an upregulated activity of catabolism by the enhanced activation of AMP kinase occurs (64). Another specific side-effect of vismodegib is dysgeusia. Tasting sweet as sour or salty, permanent metallic taste, and the complete loss of tasting ability were common complains (61). This can further aggravate weight loss, as it could lead to decrease in appetite or aversion to particular food. However, Le Moigne and colleagues were not able to find any statistical correlation between dysgeusia and weight loss (63).

Taken into consideration that vismodegib is often the last choice of therapy for laBCCs, the management of adverse events, to avoid discontinuation of the drug and subsequent development of resistance are of great importance. In our study, the suspension of vismodegib therapy increased the risk of secondary drug resistance development. Since discontinuation and suspension most commonly happen due to intolerable adverse events it is unequivocally important to adequately manage the side effects. To date, there is no widely accepted consensus on the management of Smo-inhibitor related side-effects and the occasional recommendations do not always give satisfactory outcomes (61, 65, 66). In line with this, in our study adverse events could not be fully relieved. For this reason, pharmacological therapy of side effects should be accompanied by psychological and oncological counselling. With adequate management of side effects, vismodegib therapy could be maintained with permanent efficacy and a subsequent secondary drug resistance could be prevented. It is a matter of great importance, to understand BCC carcinogenesis from the perspective of molecular genetics. As sporadic laBCC can more commonly develop due to other mutations of HH pathway than PTCH1, contrary to NBCCS, it could lead to tumors which are resistant to vismodegib and other Smo-inhibitors. This further justifies the necessity of the investigation and identification of novel targeted therapies. Also, the combination of treatments with different modes of action could result in a better efficacy and overcome acquired resistance.

In our second project, we investigated the efficacy and tolerability of high-dose IVA in laBCC either when the patient also had NBCCS or he or she did not have NBCCS. This was the first report of administering IVA for the treatment of laBCCs. Our results showed that even in the case of large and extensive BCCs high dose is well tolerated and is a completely safe therapeutic option. Side-effects were not severe and appeared only temporarily in this carefully selected group of patients. Relatively high doses were well tolerated even when administered through a peripheral vein. Nevertheless, it is important to emphasize that much higher doses could be tolerated when administered through a port-a-cath device. In contrast to Smo-inhibitors, high-dose IVA does not cause severe and intolerable side-effects. In particular lesions we could observe a PR or stable response.

In other studies, which addressed the effect of high-dose IVA on tumors, it has been suggested that different pathways are targeted at the same time (43, 67).

The adequate function of glucose transporter-1 (GLUT-1), GLUT-3 transporter and sodium dependent vitamin C transporter-2 (SVCT-2) is necessary for transportation of ascorbate into the intracellular space (68, 69). In the Warburg effect the cancer cells mainly gain energy from glycolysis and subsequent lactic acid fermentation in the cell cytoplasm, therefore these glucose transport channels are upregulated to suffice the increased need for glycolysis (70, 71). This feature of tumor cells may cause an ability to uptake of a higher concentrate of ascorbate into the intracellular space (72, 73).

Ascorbate is widely recognized as a potent antioxidant. In contrast to this fact it has been proven, that in particular conditions, such as presence of Fe^{2+}, it exerts pro-oxidant effects through the production of high concentration of reactive oxygen species (ROS), as mainly in form of hydrogen peroxide (H_2O_2) and although to a lesser extend as hydroxyl radical ($HO^{\cdot}$) (33, 36). It was proposed that H_2O_2 causes damage in the deoxyribonucleic acid (DNA) structure (74, 75). This can subsequently enhance poly-ADP-ribose polymerase (PARP) activity, which in turn consumes oxidized form of nicotinamide adenine dinucleotide (NAD+) and as a result inhibits reduced nicotinamide adenine dinucleotide (NADH) generation. The depletion of NADH leads to reduction of adenine trinucleotide phosphate (ATP) formation (76-78). Shortage of ATP could then inhibit ATP synthase (67, 79). The lack of adequate amounts of ATP can aggravate the disfunction of glutathione pathway, which has a main role in the elimination of hydrogen peroxide (67, 76). In cancer patients ferritin level, as an acute-phase agent, is generally relatively high (80). Ascorbate also has the ability to deliberate iron from ferritin to become a source for Fe^{2+} and it consequently increases H_2O_2 production in addition (81).

As BCC is a tumor that generally shows a relatively slow progression it could be postulated that it has a lower metabolic activity, and thus is less sensitive to the depletion of ATP. The fact that we did not observe any improvement in the markedly slowly growing and less vascularised adenoid type BCCs during high-dose IVA therapy in contrast to the most cases of the more aggressive micronodular type BCCs, also supports this idea (55, 82).

In our study to evaluate the pro-oxidant killing effect of ascorbate on *C. albicans* we assumed that the antifungal effect also depends on the actual conditions. Our results revealed that O_2 concentration played a significant role in ascorbate's pro-oxidant potential. These finding was consistent with Vilcheze et al.'s study where the group

showed the killing potential of ascorbate on Mycobacterium tuberculosis cells [10]. In previous studies, cell-permeable intracellular iron chelator deferoxamine mesylate has been shown to inhibit cytotoxic effects of ascorbate (83). This finding was further supported by our results, such that use of iron-chelator bipyridil could inhibit the killing effect of ascorbic acid on C.albicans. Furthermore, our results showed that the inhibition of ETC with antimycin lead to the enhanced killing effect of ascorbate in the presence of oxygen. It could be reasoned, as the use of antimycin enhance the production of ROS in the mitochondria (49).

It is unequivocal that ascorbate needs a specific microenvironment to exert it pro-oxidant killing effect both on tumor cells and fungal cells. Due to multifaceted nature of this microenvironment it is rather hard to predict when will ascorbate be ineffective or deliver only partial response.

Therefore, it is cumbersome to determine which causes can explain the only moderate effect of high-dose IVA on laBCC, and further studies are needed to reveal how, if at all, we can improve the efficacy of IVA on BCC. Taken together, we conclude that IVA monotherapy, even in a high dose such as 175 g / infusion, does not show a dramatic effect, that could lead to CR. The investigation of such a small group of patients (n=4) especially without a placebo-controlled cohort of patients constitute important limitations to this study. Lastly, the infusions must be administered three times a week and each occasion of administration is quite time consuming that makes the treatment a nuisance for the patients, and impractical. Taken together Smo-inhibitor vismodegib is still the most effective treatment of laBCCs, thus it should be the first choice of therapy in inoperable and otherwise incurable cases of BCCs. However, as high-dose IVA does not cause remarkable side-effects, it makes this treatment modality only a good candidate as an adjuvant therapy in selected cases. In case of development of a partial loss of efficacy to vismodegib, and when PD1-inhibitor could not be a choice of treatment, combining vismodegib with high-dose IVA might be considered as an option. At the same time, whether this interaction may hinder or potentiate the effects of Smo-inhibitors warrants further investigation.

6. Conclusions

6.1 Project I.

In our experiment 7 of 11 patients treated with vismodegib achieved PR or CR, which is comparable to the ratio that had been reported in the literature (46-66%) (25). In cases of patients with malignancies other than laBCCs we did not observe any tumor progression. We can state that in case of prostate, bladder cancer, polycytemia vera and meningioma vismodegib can be safely administered, however it would need further investigation with a larger sample size. Prostate cancer even improved during vismodegib treatment, but its correlation is questionable and would need further studies. We have demonstrated that a relatively high proportion, 5 of 11 of patients discontinued the therapy due to severe side effects. In comparison to the previous ERIVANCE BCC trial, our discontinuation rate is higher (45 vs. 17%). It could possibly be explained by the different features of patient groups, as ERIVANCE BCC trial included patients with metastatic BCC. This patient group is more likely to adhere to therapy despite the severe side effects as no other options are available. In order of likeliness to occur, adverse events were the following: weight loss, dysgeusia, muscle cramps and alopecia. Grades of the side-effects ranged between 1 to 3, no Grade 4 was observed. For alopecia, and dysgeusia none of the treatment modalities were found to be effective. In order to maintain weight during therapy, enhanced oral nutrition supplementation was given, and this led to only temporary success. Best-managed side effect was muscle crump, as combination of central muscle relaxants gave at least a moderate efficacy in terms of control of unwanted muscle contractions. In our study no primary resistance was observed. Secondary resistance developed in 2 of our cases, both after a temporary suspension of the treatment. Interestingly, both of these secondary resistance cases occurred in the non-NBCCS group. Our rate was higher when compared to other data in literature that showed 13% of non-NBCCS patients developed secondary resistance (30). On the other hand, although an earlier study observed development of secondary resistance in 60% of the NBCCS patients, in our study no secondary resistance could be detected in this patient group. This finding should be further examined, as NBCCS patients generally need the therapy drug for a longer period of time and a temporary suspension of drug at certain time intervals

would enable them to tolerate and in turn continue the treatment for the required amount of time.

6.2 Project II.

In our pilot study with the use of high-dose IVA therapy for laBCC we could achieve stable disease 3 out of 4 cases, and in one case we observed progressive disease in the overall response. When compared to results achieved by the Smo-inhibitor vismodegib treatment, high-dose IVA is clearly inferior to vismodegib. Based on this experiment we concluded that the first-choice treatment for otherwise incurable laBCC should be vismodegib. As high-dose IVA showed beneficial effect in 83% of all lesions and a 4-16% change in those lesions that showed reduction in size, high-dose IVA could be further investigated as a potential adjuvant treatment. It must be noted that when the dose exceeded 75 g per infusion, it had to be given through a Port-A-Cath device to prevent damage of peripheral vein. The potential use of high-dose IVA is further supported by the fact, that this therapy regimen, even in cases of 125 to 175 g per infusion, did not cause any severe side effects for a 42 ± 23.6 weeks period of time. Grade 1 nausea occasionally appeared in case of patient 1, and no other systemic side effects could be detected, aside from a mild burning sensation in the peripheral vein due to the administration of the IVA. Adenoid type BCC lesions, which are less vascularised as confirmed by CD31 staining, showed no reduction in size to IVA therapy. Some lesions of more aggressive micronodular type showed response clinically. In contrast to this, other lesions of the same histology type progressed despite high-dose IVA therapy. We could not reveal why tumors with the same histology type respond so differently; therefore, we could not explain why high-dose IVA could not exert anti-tumor effect on selected lesions. Further studies, taking the complex intra- and extracellular microenvironmental factors, level of vascularization of individual lesions, the subsequent oxygenation, metabolic activity and Fe^{2+} levels of the tumor cells, into consideration, are needed to reveal how the efficacy of IVA could be enhanced.

6.3 Project III.

Ascorbate could kill completely *C. albicans* in PBS media at 37°C, when adequate oxygenation is provided with shaking. In another experimental setup the inhibition of ETC with antimycin boosted the efficacy of ascorbate to kill *C. albicans*. We could assume that this can be further explained with the increased oxidative stress and subsequently elevated H_2O_2 concentration. Our attempt to assess the effect that the concentration of Fe^{2+} can exert on the killing potential of ascorbate revealed that cell-permeable iron-chelator bipyridil could inhibit the killing effect of ascorbate, thus free Fe^{2+} is essential to ascorbate to exert its antifungal killing potential.

7. Summary

Basal cell carcinoma is the most common malignancy of the Caucasian race with a 20-30% lifetime prevalence. The incidence is constantly increasing and consequently the cost burden on the health care system (1, 3). Associated mortality is very low, as it metastasizes only extreme rarely. However, in case of hereditary NBCCS, laBCC can develop, and by way of severe local tissue destruction it can lead to death. The gold standard in the treatment of uncomplicated BCCs is surgical excision. Still, in cases of the aformentioned otherwise incurable laBCCs an alternative to surgery is needed. The Smo-inhibitor vismodegib drug revolutionized the treatment of such cases. In our experience an excellent efficacy has been seen (64% ORR), comparable to data in the literature (25). Even when treating patients with coexisting malignancies, as e.g. prostate cancer or polycytemia vera we observed a safe administration of vismodegib. It caused side effects in all patients and nearly half of them discontinued vismodegib therapy. The management of side effects was generally unsatisfactory, it needs further investigations to improve them. Interruption of the therapy led to acquired resistance in some cases. Resistance to vismodegib, when PD1-inhibitor are also contraindicated, establish the need for further treatment options. In our pilot study we could safely administrate high dose of IVA, as up to 175 g per infusion without any relevant side-effects. We could demonstrate therapeutic efficacy as 3 of 4 patients achieved SD. IVA has led to some improvement in 83% of all lesions. We observed a relatively great difference between lesion in extent of therapeutic response, most notable adenoid type lesions did not show any change to therapy. Our study showed that the killing effect of ascorbate on *C. albicans* depends on factors as functional ETC and free iron levels. Based on these finding and the variations in therapy response between different BCCs, the only moderate overall therapeutic effect could be possibly explained by many factors, as rate of vascularisation, metabolic activity and other microenvironmental elements, such as free Fe^{2+} level in the tumors. Nevertheless, we concluded that Smo-inhibitor vismodegib needs to be the first choice of therapy in inoperable and otherwise incurable cases of BCCs. High-dose IVA therapy could only be a choice of treatment as an adjuvant therapy in therapy resistant cases, as it only supersedes vismodegib in terms of side-effect profile.

8. References

1. Reinau D, Surber C, Jick SS, Meier CR. (2014) Epidemiology of basal cell carcinoma in the United Kingdom: incidence, lifestyle factors, and comorbidities. Br J Cancer, 111: 203-206.
2. Sekulic A, Migden MR, Oro AE, Dirix L, Lewis KD, Hainsworth JD, Solomon JA, Yoo S, Arron ST, Friedlander PA, Marmur E, Rudin CM, Chang AL, Low JA, Mackey HM, Yauch RL, Graham RA, Reddy JC, Hauschild A. (2012) Efficacy and safety of vismodegib in advanced basal-cell carcinoma. N Engl J Med, 366: 2171-2179.
3. Lear W, Dahlke E, Murray CA. (2007) Basal cell carcinoma: review of epidemiology, pathogenesis, and associated risk factors. J Cutan Med Surg, 11: 19-30.
4. Pino LC, Balassiano LK, Sessim M, de Almeida AP, Empinotti VD, Semenovitch I, Treu C, Lupi O. (2016) Basal cell nevus syndrome: clinical and molecular review and case report. Int J Dermatol, 55: 367-375.
5. Khamaysi Z, Bochner R, Indelman M, Magal L, Avitan-Hersh E, Sarig O, Sprecher E, Bergman R. (2016) Segmental basal cell naevus syndrome caused by an activating mutation in smoothened. Br J Dermatol, 175: 178-181.
6. Lam C, Ou JC, Billingsley EM. (2013) "PTCH"-ing it together: a basal cell nevus syndrome review. Dermatol Surg, 39: 1557-1572.
7. Nikolaou V, Stratigos AJ, Tsao H. (2012) Hereditary nonmelanoma skin cancer. Semin Cutan Med Surg, 31: 204-210.
8. Pastorino L, Ghiorzo P, Nasti S, Battistuzzi L, Cusano R, Marzocchi C, Garre ML, Clementi M, Scarra GB. (2009) Identification of a SUFU germline mutation in a family with Gorlin syndrome. Am J Med Genet A, 149A: 1539-1543.
9. Ahn RS. (2016) Not the usual suspect: a case of basal cell naevus syndrome caused by a SMO mutation alone. Br J Dermatol, 175: 21-22.
10. Suzman DL, Antonarakis ES. (2015) Clinical Implications of Hedgehog Pathway Signaling in Prostate Cancer. Cancers (Basel), 7: 1983-1993.

11. Rimkus TK, Carpenter RL, Qasem S, Chan M, Lo HW. (2016) Targeting the Sonic Hedgehog Signaling Pathway: Review of Smoothened and GLI Inhibitors. Cancers (Basel), 8.
12. Lo Muzio L. (2008) Nevoid basal cell carcinoma syndrome (Gorlin syndrome). Orphanet J Rare Dis, 3: 32.
13. Lam CW, Xie J, To KF, Ng HK, Lee KC, Yuen NW, Lim PL, Chan LY, Tong SF, McCormick F. (1999) A frequent activated smoothened mutation in sporadic basal cell carcinomas. Oncogene, 18: 833-836.
14. Xie J, Murone M, Luoh SM, Ryan A, Gu Q, Zhang C, Bonifas JM, Lam CW, Hynes M, Goddard A, Rosenthal A, Epstein EH, Jr., de Sauvage FJ. (1998) Activating Smoothened mutations in sporadic basal-cell carcinoma. Nature, 391: 90-92.
15. Telfer NR, Colver GB, Morton CA, British Association of D. (2008) Guidelines for the management of basal cell carcinoma. Br J Dermatol, 159: 35-48.
16. Cameron MC, Lee E, Hibler BP, Giordano CN, Barker CA, Mori S, Cordova M, Nehal KS, Rossi AM. (2019) Basal cell carcinoma: Contemporary approaches to diagnosis, treatment, and prevention. J Am Acad Dermatol, 80: 321-339.
17. Baker S, Joseph K, Tai P. (2016) Radiotherapy in Gorlin Syndrome: Can It Be Safe and Effective in Adult Patients? J Cutan Med Surg, 20: 159-162.
18. Matei C, Tampa M, Poteca T, Panea-Paunica G, Georgescu SR, Ion RM, Popescu SM, Giurcaneanu C. (2013) Photodynamic therapy in the treatment of basal cell carcinoma. J Med Life, 6: 50-54.
19. Sekulic A, Migden MR, Lewis K, Hainsworth JD, Solomon JA, Yoo S, Arron ST, Friedlander PA, Marmur E, Rudin CM, Chang AL, Dirix L, Hou J, Yue H, Hauschild A, investigators EB. (2015) Pivotal ERIVANCE basal cell carcinoma (BCC) study: 12-month update of efficacy and safety of vismodegib in advanced BCC. J Am Acad Dermatol, 72: 1021-1026 e1028.
20. Jain S, Song R, Xie J. (2017) Sonidegib: mechanism of action, pharmacology, and clinical utility for advanced basal cell carcinomas. Onco Targets Ther, 10: 1645-1653.
21. Sekulic A, Migden MR, Basset-Seguin N, Garbe C, Gesierich A, Lao CD, Miller C, Mortier L, Murrell DF, Hamid O, Quevedo JF, Hou J, McKenna E, Dimier N,

Williams S, Schadendorf D, Hauschild A, Investigators EB. (2017) Long-term safety and efficacy of vismodegib in patients with advanced basal cell carcinoma: final update of the pivotal ERIVANCE BCC study. BMC Cancer, 17: 332.

22. Frampton JE, Basset-Seguin N. (2018) Vismodegib: A Review in Advanced Basal Cell Carcinoma. Drugs, 78: 1145-1156.

23. Elia D, Madhala D, Ardon E, Reshef R, Halevy O. (2007) Sonic hedgehog promotes proliferation and differentiation of adult muscle cells: Involvement of MAPK/ERK and PI3K/Akt pathways. Biochim Biophys Acta, 1773: 1438-1446.

24. Ally MS, Tang JY, Lindgren J, Acosta-Raphael M, Rezaee M, Chanana AM, Epstein EH, Jr. (2015) Effect of Calcium Channel Blockade on Vismodegib-Induced Muscle Cramps. JAMA Dermatol, 151: 1132-1134.

25. Lacouture ME, Dreno B, Ascierto PA, Dummer R, Basset-Seguin N, Fife K, Ernst S, Licitra L, Neves RI, Peris K, Puig S, Sokolof J, Sekulic A, Hauschild A, Kunstfeld R. (2016) Characterization and Management of Hedgehog Pathway Inhibitor-Related Adverse Events in Patients With Advanced Basal Cell Carcinoma. Oncologist, 21: 1218-1229.

26. Paladini RD, Saleh J, Qian C, Xu GX, Rubin LL. (2005) Modulation of hair growth with small molecule agonists of the hedgehog signaling pathway. J Invest Dermatol, 125: 638-646.

27. Ermilov AN, Kumari A, Li L, Joiner AM, Grachtchouk MA, Allen BL, Dlugosz AA, Mistretta CM. (2016) Maintenance of Taste Organs Is Strictly Dependent on Epithelial Hedgehog/GLI Signaling. PLoS Genet, 12: e1006442.

28. Fellner C. (2012) Vismodegib (erivedge) for advanced Basal cell carcinoma. P T, 37: 670-682.

29. Pricl S, Cortelazzi B, Dal Col V, Marson D, Laurini E, Fermeglia M, Licitra L, Pilotti S, Bossi P, Perrone F. (2015) Smoothened (SMO) receptor mutations dictate resistance to vismodegib in basal cell carcinoma. Mol Oncol, 9: 389-397.

30. Chang AL, Oro AE. (2012) Initial assessment of tumor regrowth after vismodegib in advanced Basal cell carcinoma. Arch Dermatol, 148: 1324-1325.

31. Zhu GA, Li AS, Chang AL. (2014) Patient with Gorlin syndrome and metastatic basal cell carcinoma refractory to smoothened inhibitors. JAMA Dermatol, 150: 877-879.

32. Lipson EJ, Lilo MT, Ogurtsova A, Esandrio J, Xu H, Brothers P, Schollenberger M, Sharfman WH, Taube JM. (2017) Basal cell carcinoma: PD-L1/PD-1 checkpoint expression and tumor regression after PD-1 blockade. J Immunother Cancer, 5: 23.
33. Du J, Cullen JJ, Buettner GR. (2012) Ascorbic acid: chemistry, biology and the treatment of cancer. Biochim Biophys Acta, 1826: 443-457.
34. Du J, Martin SM, Levine M, Wagner BA, Buettner GR, Wang SH, Taghiyev AF, Du C, Knudson CM, Cullen JJ. (2010) Mechanisms of ascorbate-induced cytotoxicity in pancreatic cancer. Clin Cancer Res, 16: 509-520.
35. Shatzer AN, Espey MG, Chavez M, Tu H, Levine M, Cohen JI. (2013) Ascorbic acid kills Epstein-Barr virus positive Burkitt lymphoma cells and Epstein-Barr virus transformed B-cells in vitro, but not in vivo. Leuk Lymphoma, 54: 1069-1078.
36. Vilcheze C, Hartman T, Weinrick B, Jacobs WR, Jr. (2013) Mycobacterium tuberculosis is extraordinarily sensitive to killing by a vitamin C-induced Fenton reaction. Nat Commun, 4: 1881.
37. Tabak M, Armon R, Rosenblat G, Stermer E, Neeman I. (2003) Diverse effects of ascorbic acid and palmitoyl ascorbate on Helicobacter pylori survival and growth. FEMS Microbiol Lett, 224: 247-253.
38. Brajtburg J, Elberg S, Kobayashi GS, Medoff G. (1989) Effects of ascorbic acid on the antifungal action of amphotericin B. J Antimicrob Chemother, 24: 333-337.
39. Leelahavanichkul A, Somparn P, Bootprapan T, Tu H, Tangtanatakul P, Nuengjumnong R, Worasilchai N, Tiranathanagul K, Eiam-ong S, Levine M, Chinampon A, Srisawat N. (2015) High-dose ascorbate with low-dose amphotericin B attenuates severity of disease in a model of the reappearance of candidemia during sepsis in the mouse. Am J Physiol Regul Integr Comp Physiol, 309: R223-234.
40. Avci P, Freire F, Banvolgyi A, Mylonakis E, Wikonkal NM, Hamblin MR. (2016) Sodium ascorbate kills Candida albicans in vitro via iron-catalyzed Fenton reaction: importance of oxygenation and metabolism. Future Microbiol, 11: 1535-1547.

41. Wilson MK, Baguley BC, Wall C, Jameson MB, Findlay MP. (2014) Review of high-dose intravenous vitamin C as an anticancer agent. Asia Pac J Clin Oncol, 10: 22-37.

42. Fritz H, Flower G, Weeks L, Cooley K, Callachan M, McGowan J, Skidmore B, Kirchner L, Seely D. (2014) Intravenous Vitamin C and Cancer: A Systematic Review. Integr Cancer Ther, 13: 280-300.

43. El Halabi I, Bejjany R, Nasr R, Mukherji D, Temraz S, Nassar FJ, El Darsa H, Shamseddine A. (2018) Ascorbic Acid in Colon Cancer: From the Basic to the Clinical Applications. Int J Mol Sci, 19.

44. Ma Y, Chapman J, Levine M, Polireddy K, Drisko J, Chen Q. (2014) High-dose parenteral ascorbate enhanced chemosensitivity of ovarian cancer and reduced toxicity of chemotherapy. Sci Transl Med, 6: 222ra218.

45. Hollo P, Jokai H, Harsing J, Soos G, Karpati S, Nemeth K. (2016) Topically applied ascorbic acid solution for the treatment of basal cell carcinoma (BCC). J Am Acad Dermatol, 75: 212-213.

46. Riordan HD, Casciari JJ, Gonzalez MJ, Riordan NH, Miranda-Massari JR, Taylor P, Jackson JA. (2005) A pilot clinical study of continuous intravenous ascorbate in terminal cancer patients. P R Health Sci J, 24: 269-276.

47. Hoffer LJ, Levine M, Assouline S, Melnychuk D, Padayatty SJ, Rosadiuk K, Rousseau C, Robitaille L, Miller WH, Jr. (2008) Phase I clinical trial of i.v. ascorbic acid in advanced malignancy. Ann Oncol, 19: 1969-1974.

48. Stephenson CM, Levin RD, Spector T, Lis CG. (2013) Phase I clinical trial to evaluate the safety, tolerability, and pharmacokinetics of high-dose intravenous ascorbic acid in patients with advanced cancer. Cancer Chemother Pharmacol, 72: 139-146.

49. Chabrier-Rosello Y, Giesselman BR, De Jesus-Andino FJ, Foster TH, Mitra S, Haidaris CG. (2010) Inhibition of electron transport chain assembly and function promotes photodynamic killing of Candida. J Photochem Photobiol B, 99: 117-125.

50. Eisenhauer EA, Therasse P, Bogaerts J, Schwartz LH, Sargent D, Ford R, Dancey J, Arbuck S, Gwyther S, Mooney M, Rubinstein L, Shankar L, Dodd L, Kaplan

R, Lacombe D, Verweij J. (2009) New response evaluation criteria in solid tumours: revised RECIST guideline (version 1.1). Eur J Cancer, 45: 228-247.

51. Enjalbert B, Rachini A, Vediyappan G, Pietrella D, Spaccapelo R, Vecchiarelli A, Brown AJ, d'Enfert C. (2009) A multifunctional, synthetic Gaussia princeps luciferase reporter for live imaging of Candida albicans infections. Infect Immun, 77: 4847-4858.

52. Cheng SH, Liu JM, Liu QY, Luo DY, Liao BH, Li H, Wang KJ. (2014) Prognostic role of microvessel density in patients with renal cell carcinoma: a meta-analysis. Int J Clin Exp Pathol, 7: 5855-5863.

53. Staibano S, Boscaino A, Salvatore G, Orabona P, Palombini L, De Rosa G. (1996) The prognostic significance of tumor angiogenesis in nonaggressive and aggressive basal cell carcinoma of the human skin. Hum Pathol, 27: 695-700.

54. Loggini B, Boldrini L, Gisfredi S, Ursino S, Camacci T, De Jeso K, Cervadoro G, Pingitore R, Barachini P, Leocata P, Fontanini G. (2003) CD34 microvessel density and VEGF expression in basal and squamous cell carcinoma. Pathol Res Pract, 199: 705-712.

55. Murkey N, Murkey P, Kalele KP, Patil KP. (2017) Adenoid Variant of Basal Cell Carcinoma: A Case Report with a Glance at Biological Behavior of the Tumor. Indian J Dermatol, 62: 103-105.

56. Staubli A, Boelsterli UA. (1998) The labile iron pool in hepatocytes: prooxidant-induced increase in free iron precedes oxidative cell injury. Am J Physiol, 274: G1031-1037.

57. Goldenberg G, Karagiannis T, Palmer JB, Lotya J, O'Neill C, Kisa R, Herrera V, Siegel DM. (2016) Incidence and prevalence of basal cell carcinoma (BCC) and locally advanced BCC (LABCC) in a large commercially insured population in the United States: A retrospective cohort study. J Am Acad Dermatol, 75: 957-966 e952.

58. Gonnissen A, Isebaert S, Haustermans K. (2013) Hedgehog signaling in prostate cancer and its therapeutic implication. Int J Mol Sci, 14: 13979-14007.

59. Laurendeau I, Ferrer M, Garrido D, D'Haene N, Ciavarelli P, Basso A, Vidaud M, Bieche I, Salmon I, Szijan I. (2010) Gene expression profiling of the hedgehog signaling pathway in human meningiomas. Mol Med, 16: 262-270.

60. Erdem GU, Sendur MA, Ozdemir NY, Yazici O, Zengin N. (2015) A comprehensive review of the role of the hedgehog pathway and vismodegib in the management of basal cell carcinoma. Curr Med Res Opin, 31: 743-756.
61. Fife K, Herd R, Lalondrelle S, Plummer R, Strong A, Jones S, Lear JT. (2017) Managing adverse events associated with vismodegib in the treatment of basal cell carcinoma. Future Oncol, 13: 175-184.
62. Alkeraye S, Maire C, Desmedt E, Templier C, Mortier L. (2015) Persistent alopecia induced by vismodegib. Br J Dermatol, 172: 1671-1672.
63. Le Moigne M, Saint-Jean M, Jirka A, Quereux G, Peuvrel L, Brocard A, Gaultier A, Khammari A, Darmaun D, Dreno B. (2016) Dysgeusia and weight loss under treatment with vismodegib: benefit of nutritional management. Support Care Cancer, 24: 1689-1695.
64. Kola B. (2008) Role of AMP-activated protein kinase in the control of appetite. J Neuroendocrinol, 20: 942-951.
65. Calzavara Pinton P, Licitra L, Peris K, Santoro A, Ascierto PA. (2015) Vismodegib in the treatment of basal cell carcinoma: indications for clinical practice. Future Oncol, 11: 1429-1435.
66. Mohan SV, Chang AL. (2015) Management of Cutaneous and Extracutaneous Side Effects of Smoothened Inhibitor Therapy for Advanced Basal Cell Carcinoma. Clin Cancer Res, 21: 2677-2683.
67. Chen P, Yu J, Chalmers B, Drisko J, Yang J, Li B, Chen Q. (2012) Pharmacological ascorbate induces cytotoxicity in prostate cancer cells through ATP depletion and induction of autophagy. Anticancer Drugs, 23: 437-444.
68. Tsukaguchi H, Tokui T, Mackenzie B, Berger UV, Chen XZ, Wang Y, Brubaker RF, Hediger MA. (1999) A family of mammalian Na+-dependent L-ascorbic acid transporters. Nature, 399: 70-75.
69. Vera JC, Rivas CI, Fischbarg J, Golde DW. (1993) Mammalian facilitative hexose transporters mediate the transport of dehydroascorbic acid. Nature, 364: 79-82.
70. Warburg O. (1956) On the origin of cancer cells. Science, 123: 309-314.
71. Hsu PP, Sabatini DM. (2008) Cancer cell metabolism: Warburg and beyond. Cell, 134: 703-707.

72. Krzeslak A, Wojcik-Krowiranda K, Forma E, Jozwiak P, Romanowicz H, Bienkiewicz A, Brys M. (2012) Expression of GLUT1 and GLUT3 glucose transporters in endometrial and breast cancers. Pathol Oncol Res, 18: 721-728.
73. Macheda ML, Rogers S, Best JD. (2005) Molecular and cellular regulation of glucose transporter (GLUT) proteins in cancer. J Cell Physiol, 202: 654-662.
74. Imlay JA, Chin SM, Linn S. (1988) Toxic DNA damage by hydrogen peroxide through the Fenton reaction in vivo and in vitro. Science, 240: 640-642.
75. Valko M, Jomova K, Rhodes CJ, Kuca K, Musilek K. (2016) Redox- and non-redox-metal-induced formation of free radicals and their role in human disease. Arch Toxicol, 90: 1-37.
76. Yun J, Mullarky E, Lu C, Bosch KN, Kavalier A, Rivera K, Roper J, Chio, II, Giannopoulou EG, Rago C, Muley A, Asara JM, Paik J, Elemento O, Chen Z, Pappin DJ, Dow LE, Papadopoulos N, Gross SS, Cantley LC. (2015) Vitamin C selectively kills KRAS and BRAF mutant colorectal cancer cells by targeting GAPDH. Science, 350: 1391-1396.
77. Verrax J, Vanbever S, Stockis J, Taper H, Calderon PB. (2007) Role of glycolysis inhibition and poly(ADP-ribose) polymerase activation in necrotic-like cell death caused by ascorbate/menadione-induced oxidative stress in K562 human chronic myelogenous leukemic cells. Int J Cancer, 120: 1192-1197.
78. Schraufstatter IU, Hinshaw DB, Hyslop PA, Spragg RG, Cochrane CG. (1986) Oxidant injury of cells. DNA strand-breaks activate polyadenosine diphosphate-ribose polymerase and lead to depletion of nicotinamide adenine dinucleotide. J Clin Invest, 77: 1312-1320.
79. Ahmad IM, Aykin-Burns N, Sim JE, Walsh SA, Higashikubo R, Buettner GR, Venkataraman S, Mackey MA, Flanagan SW, Oberley LW, Spitz DR. (2005) Mitochondrial O2*- and H2O2 mediate glucose deprivation-induced stress in human cancer cells. J Biol Chem, 280: 4254-4263.
80. Alkhateeb AA, Connor JR. (2013) The significance of ferritin in cancer: anti-oxidation, inflammation and tumorigenesis. Biochim Biophys Acta, 1836: 245-254.
81. Baader SL, Bruchelt G, Carmine TC, Lode HN, Rieth AG, Niethammer D. (1994) Ascorbic-acid-mediated iron release from cellular ferritin and its relation to the

formation of DNA strand breaks in neuroblastoma cells. J Cancer Res Clin Oncol, 120: 415-421.

82. Carbone A, Viola P, Varrati S, Angelucci D, Tulli A, Amerio P. (2011) Microvessel density and VEGF expression seems to correlate with invasiveness of basal cell carcinoma. Eur J Dermatol, 21: 608-609.

83. Duarte TL, Almeida GM, Jones GD. (2007) Investigation of the role of extracellular H2O2 and transition metal ions in the genotoxic action of ascorbic acid in cell culture models. Toxicol Lett, 170: 57-65.

9. Bibliography of the candidate's publications

Publications related to the dissertation:

1. **András, Bánvölgyi** ; Kende, Lőrincz ; Norbert, Kiss; Pinar, Avci ; Luca, Fésűs ; Róbert, Szipőcs ; Tibor, Krenács ; Nóra, Gyöngyösi ; Norbert, Wikonkál ; Sarolta, Kárpáti ; Krisztián, Németh: Efficiency of long-term high-dose intravenous ascorbic acid therapy in locally advanced basal cell carcinoma – a pilot study. ***ADVANCES IN DERMATOLOGY AND ALLERGOLOGY/POSTĘPY DERMATOLOGII I ALERGOLOGII*** (2020)
DOI: 10.5114/ada.2019.83027
IF: 1.757

2. **Bánvölgyi, A*** ; Anker, P* ; Lőrincz, K ; Kiss, N ; Márton, D ; Fésűs, L ; Gyöngyösi, N ; Wikonkál, N.: Smoothened Receptor Inhibitor Vismodegib for the Treatment of Basal Cell Carcinoma: a Retrospective Analysis of Efficacy and Side Effects ***JOURNAL OF DERMATOLOGICAL TREATMENT*** 31 : 4 p. 387 , 12 p. (2020)
DOI: 10.1080/09546634.2019.1601155
(*These authors contributed equally to this work)
IF: 2.112

3. Avci, P ; Freire, F ; **Banvolgyi, A** ; Mylonakis, E ; Wikonkal, NM ; Hamblin, MR Sodium ascorbate kills Candida albicans in vitro via iron-catalyzed Fenton reaction: importance of oxygenation and metabolism. ***FUTURE MICROBIOLOGY*** 11 : 12 pp. 1535-1547. , 13 p. (2016)
DOI: 10.2217/fmb-2016-0063
IF: 3.374

Publications not related to the dissertation:

1. Kiss Norbert; Avci Pinar; **Bánvölgyi András**; Lőrincz Kende; Szakonyi József; Gyöngyösi Nóra; Fésűs Luca; Lee Goeun; Wikonkál Norbert: Intralesional therapy for the treatment of keratoacanthoma
DERMATOLOGIC THERAPY 32 : 3 Paper: e12872 , 11 p. (2019)
IF: 1.74

2. Kiss N ; Haluszka D; Lőrincz K; Gyöngyösi N ; Bozsányi S; **Bánvölgyi A**; Szipőcs R; Wikonkál N: Quantitative Analysis on Ex Vivo Nonlinear Microscopy Images of Basal Cell Carcinoma Samples in Comparison to Healthy Skin
PATHOLOGY AND ONCOLOGY RESEARCH 25 : 3 pp. 1015-1021. , 7 p. (2019)
IF: 2.43

3. Kiss N; Krolopp Á; Lőrincz K; **Bánvölgyi A**; Szipőcs R; Wikonkál N: Stain-free Histopathology of Basal Cell Carcinoma by Dual Vibration Resonance Frequency CARS Microscopy
PATHOLOGY AND ONCOLOGY RESEARCH 24 : 4 pp. 927-930. , 4 p. (2018)
IF: 2.43

4. Lorincz K; Haluszka D; Kiss N; Gyongyosi N; **Banvolgyi A**; Szipocs R; Wikonkal NM: Voluntary exercise improves murine dermal connective tissue status in high-fat diet-induced obesity
ARCHIVES OF DERMATOLOGICAL RESEARCH 309 : 3 pp. 209-215. , 7 p. (2017)
IF: 2.3

5. Gyöngyösi Nóra; Lőrincz Kende; Keszeg András; Haluszka Dóra; **Bánvölgyi András**; Tátrai Erika; Kárpáti Sarolta; Wikonkál NM: Photosensitivity of murine skin greatly depends on the genetic background: Clinically Relevant Dose as a new measure to replace Minimal Erythema Dose in mouse studies
EXPERIMENTAL DERMATOLOGY 25 : 7 pp. 519-525. , 7 p. (2016)
IF: 2.86

6. **Bánvölgyi A**; Balla E ; Bognár P ; Tóth B; Ostorházi E ; Bánhegyi D; Kárpáti S; Marschalkó M: Lymphogranuloma venereum: első hazai esetek
ORVOSI HETILAP 156 : 1 pp. 36-40. , 5 p. (2015)
IF: 0.56

7. Tarnoki Adam Domonkos; Tarnoki David Laszlo; Kiss Katalin Klara; Bata Pal; Karlinger Kinga; **Banvolgyi Andras**; Wikonkal Norbert; Berczi, Viktor: Unusual Cortical Bone Features in a Patient with Gorlin-Goltz Syndrome: A Case Report
IRANIAN JOURNAL OF RADIOLOGY 11 : 4 Paper: e5316 , 4 p. (2014)
IF: 0.47

10. Acknowledgements

I would like to emphasize that it would not have been possible to accomplish this scientific work without the help and support of people around me, to only some of whom it is possible to give particular mention here.

First I would like to express my deepest gratitude to Professor Norbert Wikonkál for the support and professional guidance both in scientific work and in life. I consider myself especially fortunate that from the very beginning, as a subordinate, then as a co-worker and later as a friend, I have had the opportunity to acquire skills for research and the medical profession at the highest level according to his advice and suggestions. He has unconditionally encouraged me and gave me confidence to begin, to continue insistently and to complete this scientific project. His wisdom and endurance have served and will serve as a guideline throughout my whole professional work.

I would like to thank to Professor Sarolta Kárpáti, that as the head of the Clinic, she let me to become part of team of the institute. I am indebted to her for the possibility to manage the high-dose intravenous vitamin C research project.

I am also grateful to Professor Miklós Sárdy, that as the present head of the Clinic, he gave me the opportunity to continue the work with renewed energy. His enthusiasm, committed support, and professional advice provided a huge drive and help throughout the work.

I would like to acknowledge to my co-authors and friends who helped me to perform the research with their excellent talent, skills and support. I would like to thank to Kende Lőrincz who helped me with great and valuable ideas, selfless support and enthusiasm. I am deeply honored to be supported by Norbert Kiss, who helped my work with unselfish dedication, excellent precision and extensive knowledge. I owe a debt to Pinar Avci for her scientific knowledge and perpetual endurance that gave me an example and her altruistic support throughout the whole project. The time I spent with her gave me opportunity to make a new and valuable friend. In addition, I would like to thank to Nóra Gyöngyösi for her scientific support, enthusiasm and the time we can spent together during this work.

Furthermore, I also share the credit of this work with Pálma Anker, who showed impressive perseverance and professionalism toward this work. I would like to express

my gratefulness to Luca Fésűs for helping me with the experiments with her excellent skills. I am expressively thankful to Antal Jobbágy for his selfless and limitless support and work. I would like to express my obligation to Szabolcs Bozsányi to help me during the experiments. I am also thankful to Haluszka Dóra to contribute to this work.

This thesis would not have been possible without the genuine ideas and scientific professionalism of Krisztián Németh, hence I owe my deepest gratitude to him.

I am indebted to the colleagues of the histopathology lab, foremost Judit Hársing and Enikő Kuroli for their excellent histological evaluations and professional guidance that contributed greatly to this work. I would like to express my thank for the assistant staff of histology laboratory to process histological specimens

I am deeply grateful to Róbert Szipőcs to provide the possibility and the technical background of nonlinear microscopic measurements.

I am also thankful to Tibor Krenács for his excellent support and scientific advices during the projects.

It gives me great pleasure in acknowledging the support of Bernadett Hidvégi, Professor Márta Marschalkó and Márta Medvecz, who always supported me professionally and humanly at all times.

I would like to express my recognition to all employees of the Department of Dermatology, Venereology and Dermatooncology, Semmelweis University.

Finally, I cannot find words to express the deepest gratitude to my partner, my family and my friends for the past years of my doctoral studies supported by unconditional patience and deepest understanding.